

Осложненные пневмонии
(абсцесс легкого, хронические
пневмонии).

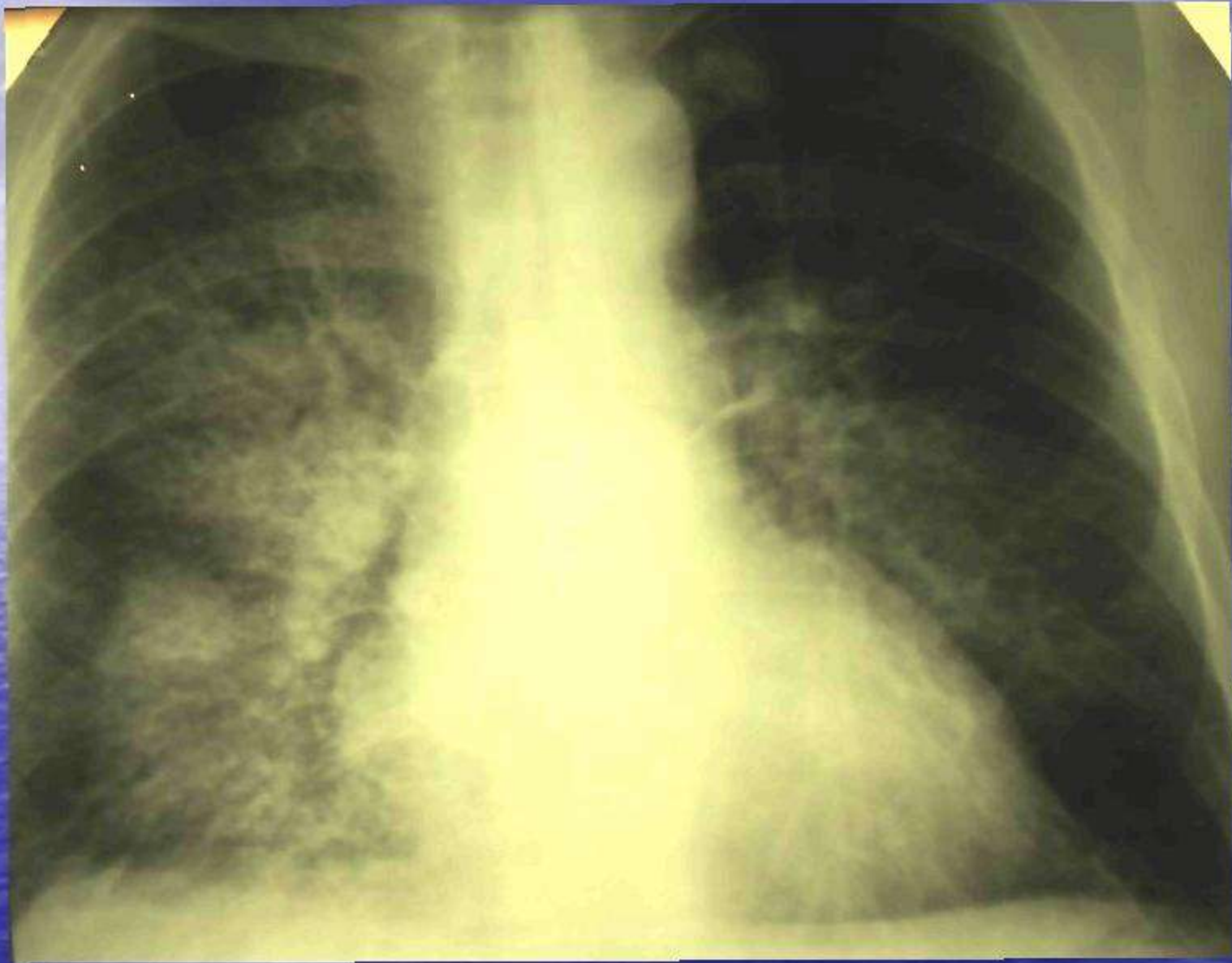
МСКТ. Наблюдения из практики.

Бодров Ю.Д. *канд. мед. наук.*

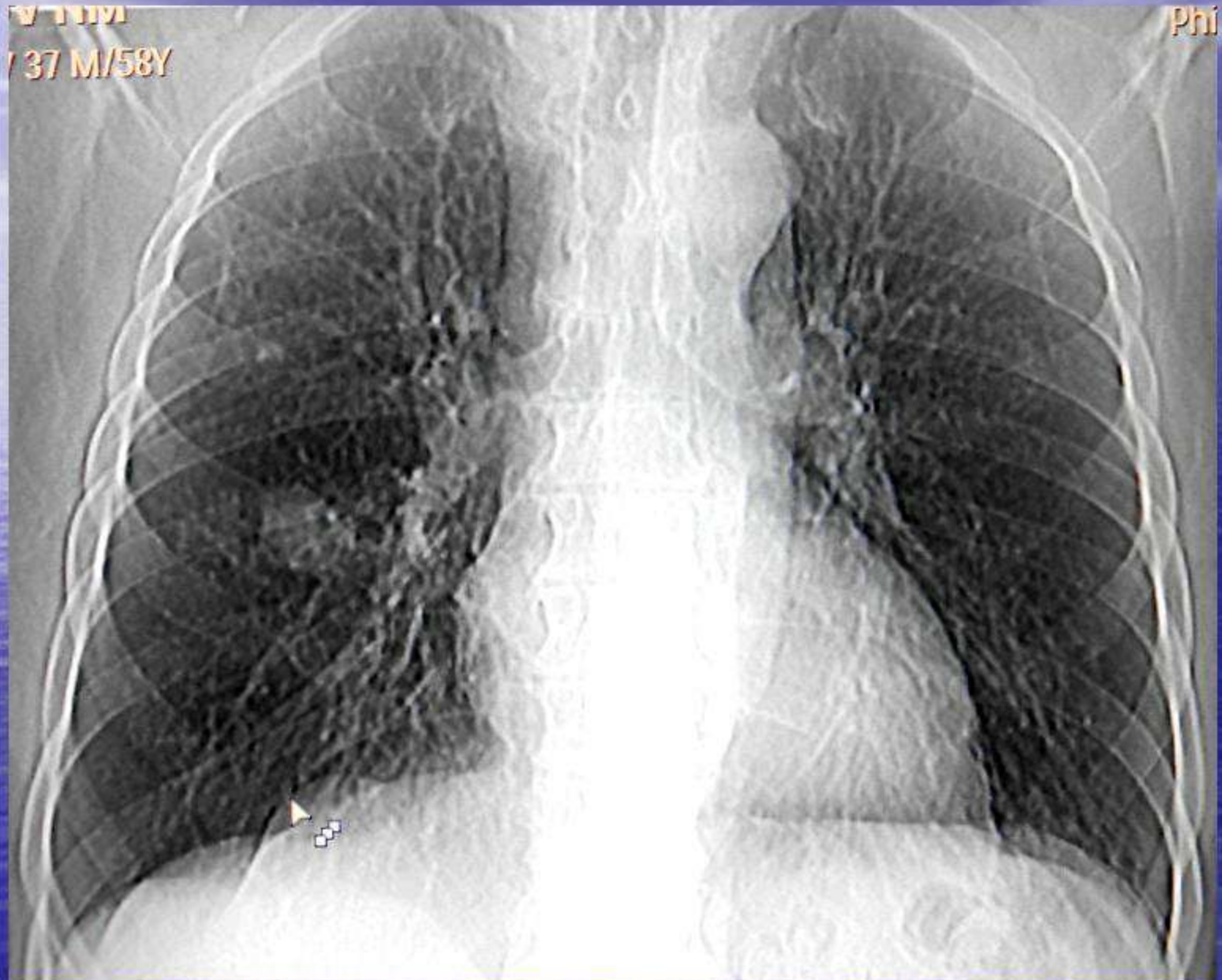
Правосторонняя
полисегментарная пневмония,
осложненная абсцессом в средней доле.
МСКТ. Наблюдение из практики.

Бодров Ю.Д. *канд. мед. наук.*

Рентгенограмма до лечения.

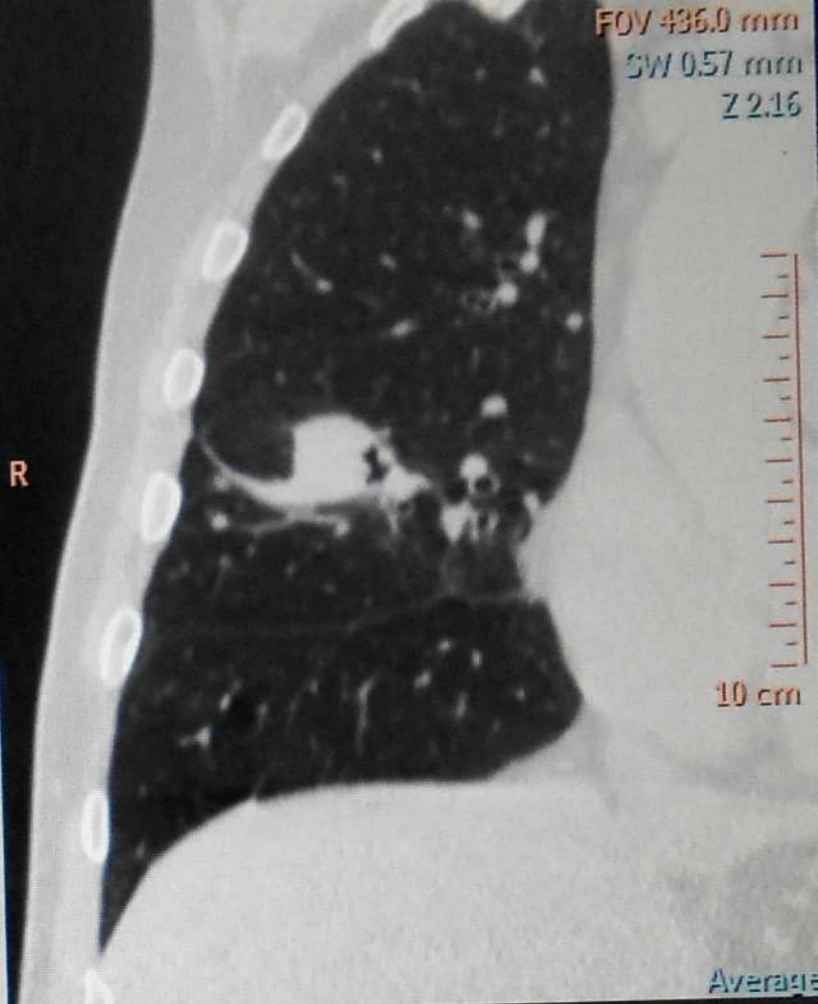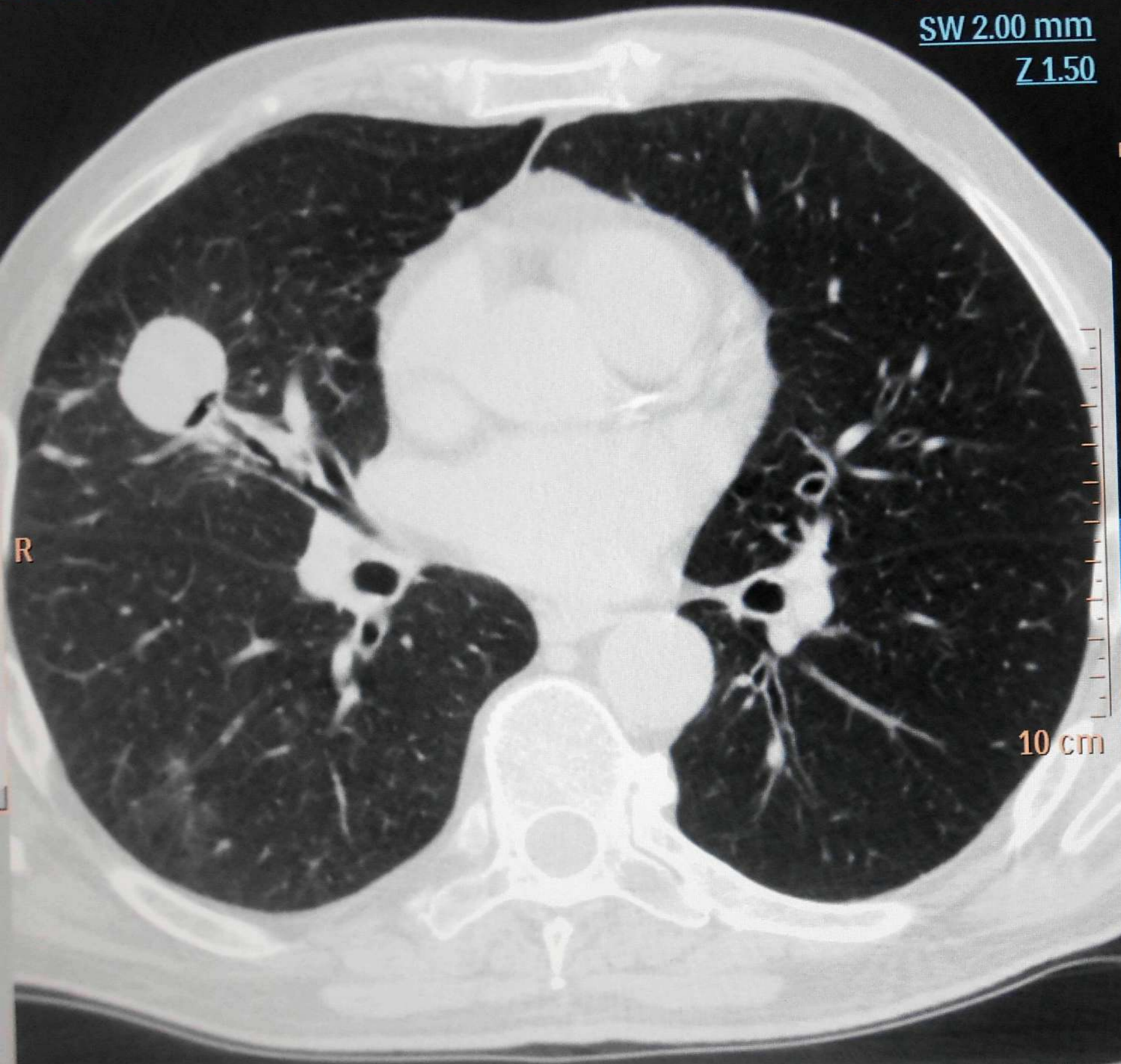


КТ топограмма через 3 недели лечения.

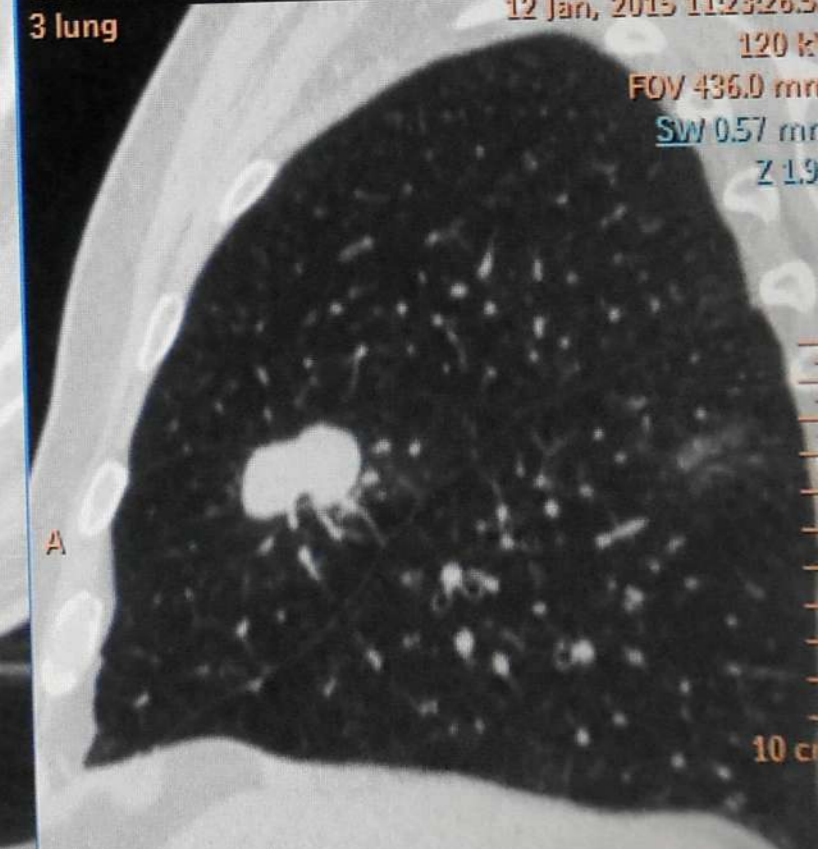


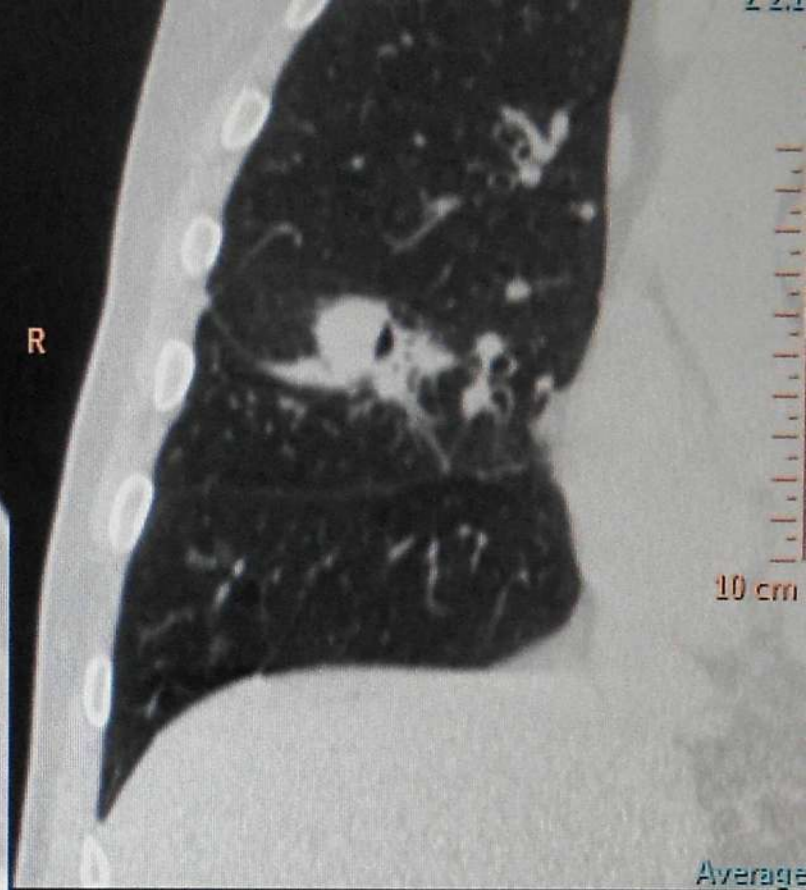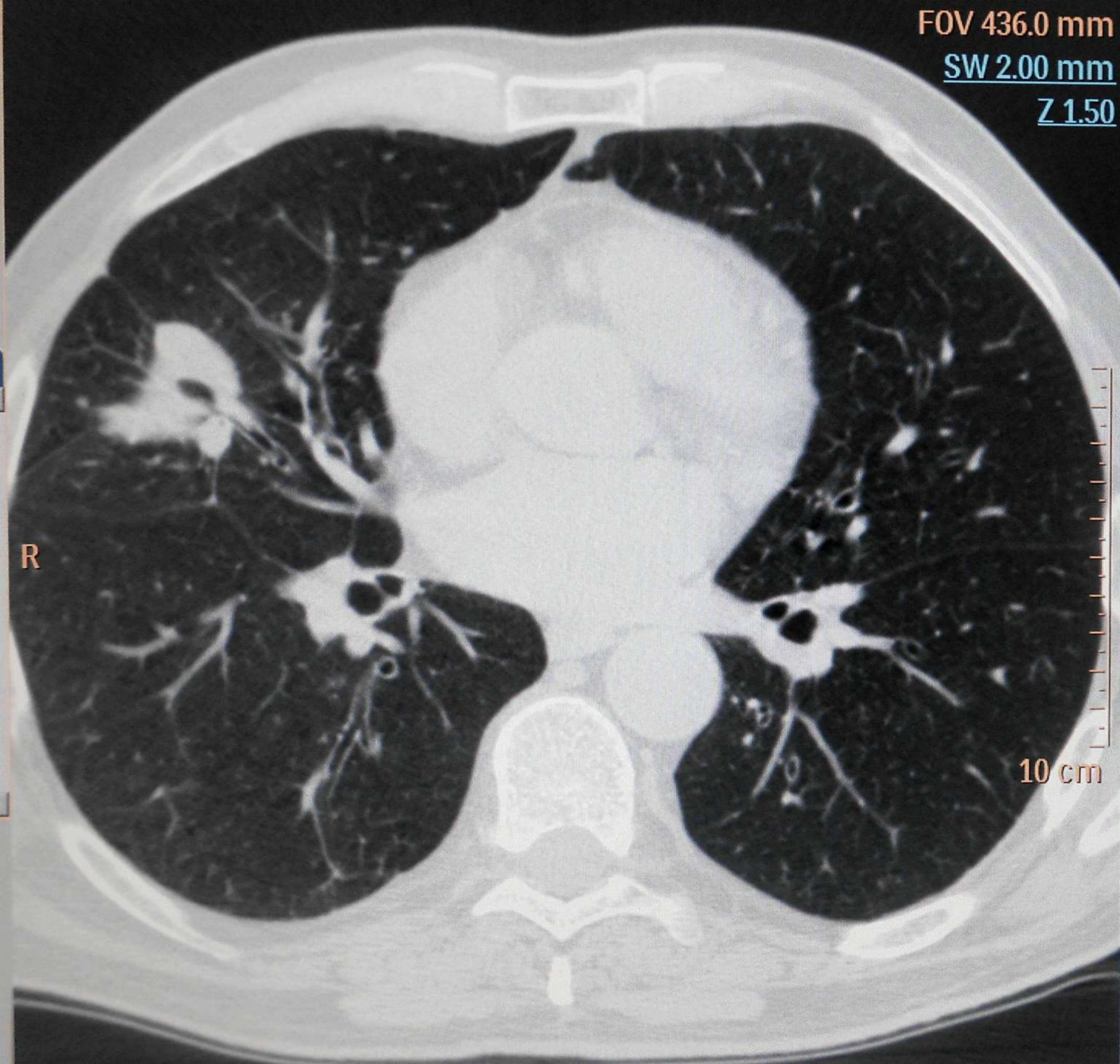
060-423-957 37 M/58Y
3-188* lung
49.3 mm

12 Jan, 2015 11:23:25.95
120 kV
FOV 436.0 mm
SW 2.00 mm
Z 1.50



Average
C -500
W 1500
F
STVETKOV NM
060-423-957 37 M/58Y
3 lung
Philips, Brilliance Big Bore
12 Jan, 2015 11:23:26.5

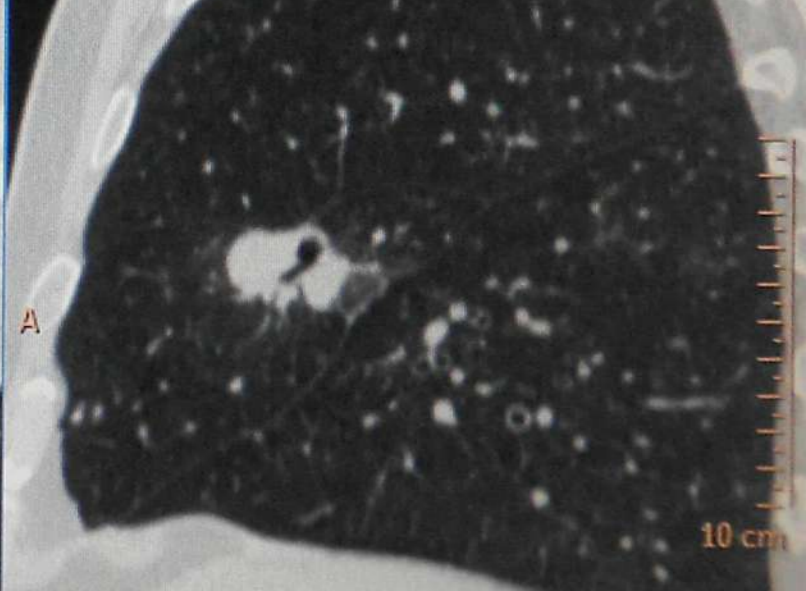


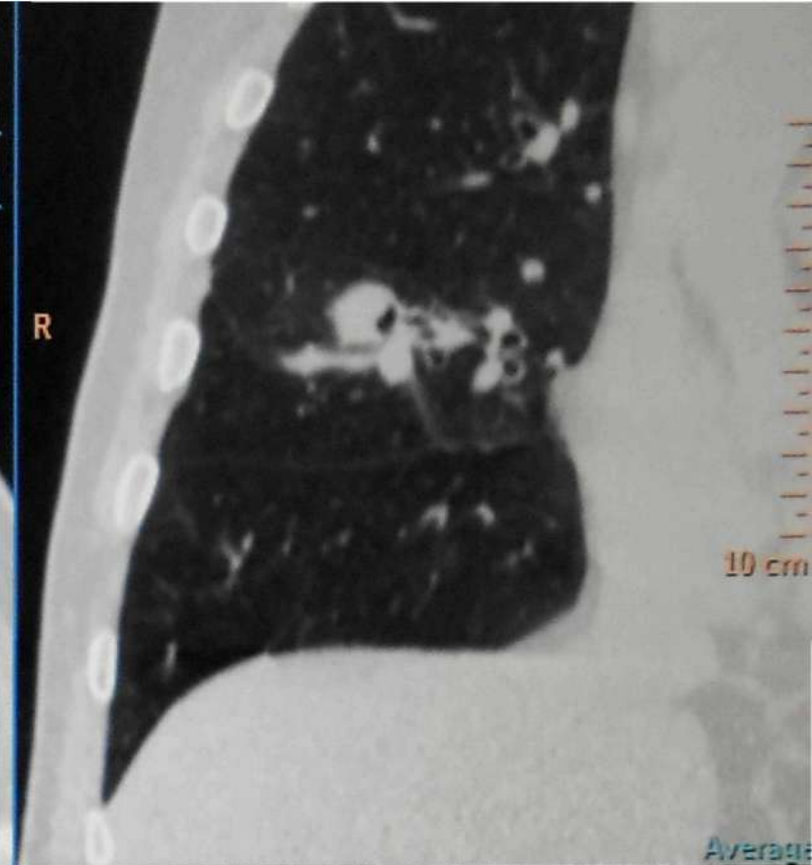
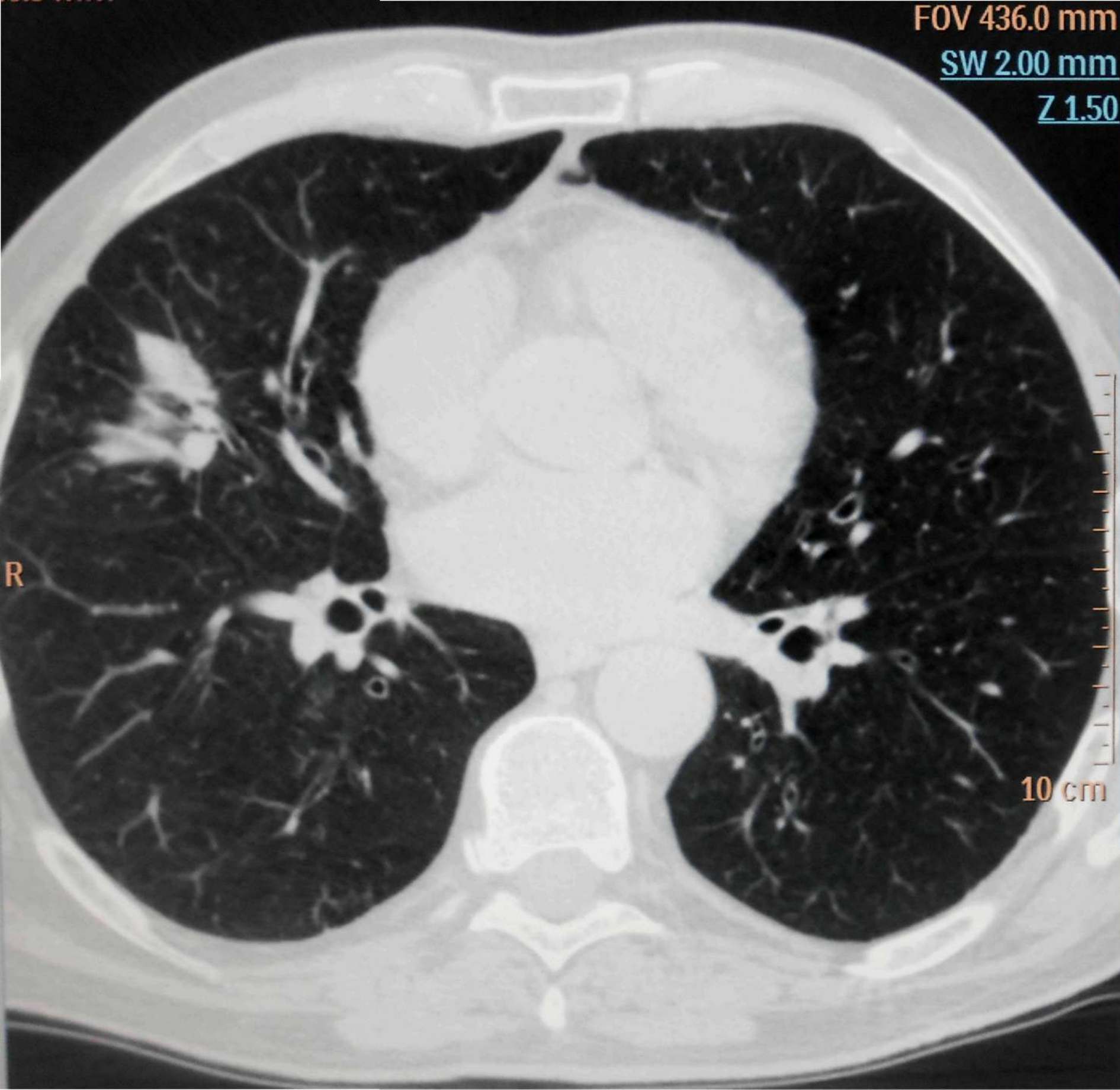


Average
C -500
W 1500
PMSTL

STVETKOV NM
060-423-957 37 M/58Y
3 lung

Philips, Brilliance Big Bore
12 Jan, 2015 11:23:26.52
120 kV
FOV 436.0 mm
SW 0.57 mm
Z 1.97

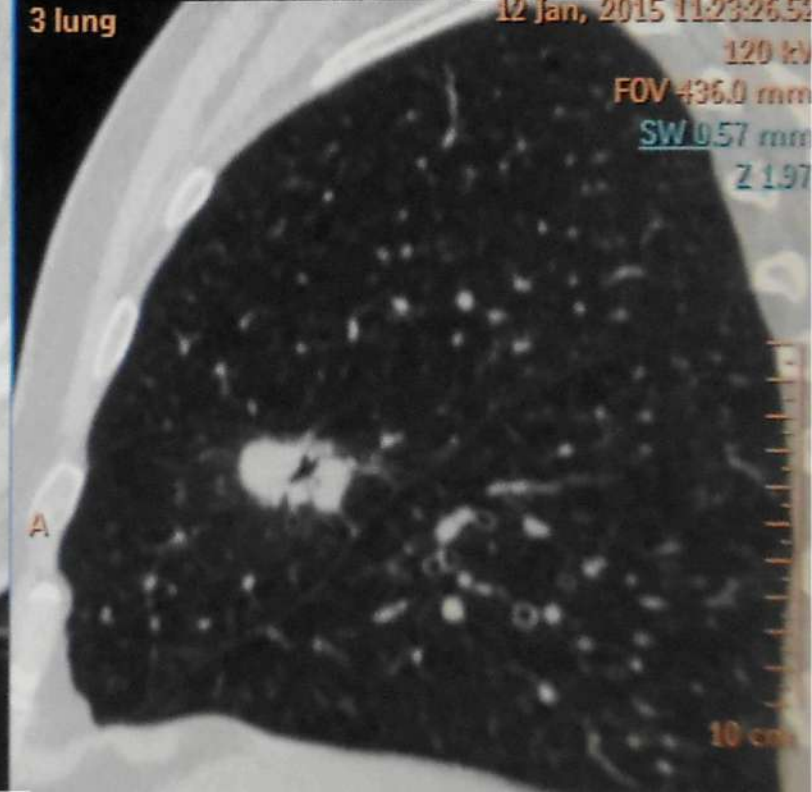



Average
C -500
W 1500
PMSTL

STVETKOV NM
060-423-957 37 M/58Y
3 lung

Philips, Brilliance Big Bore
12 Jan, 2015 11:23:26.53



060-423-957 37 M/58Y

2* soft
mm

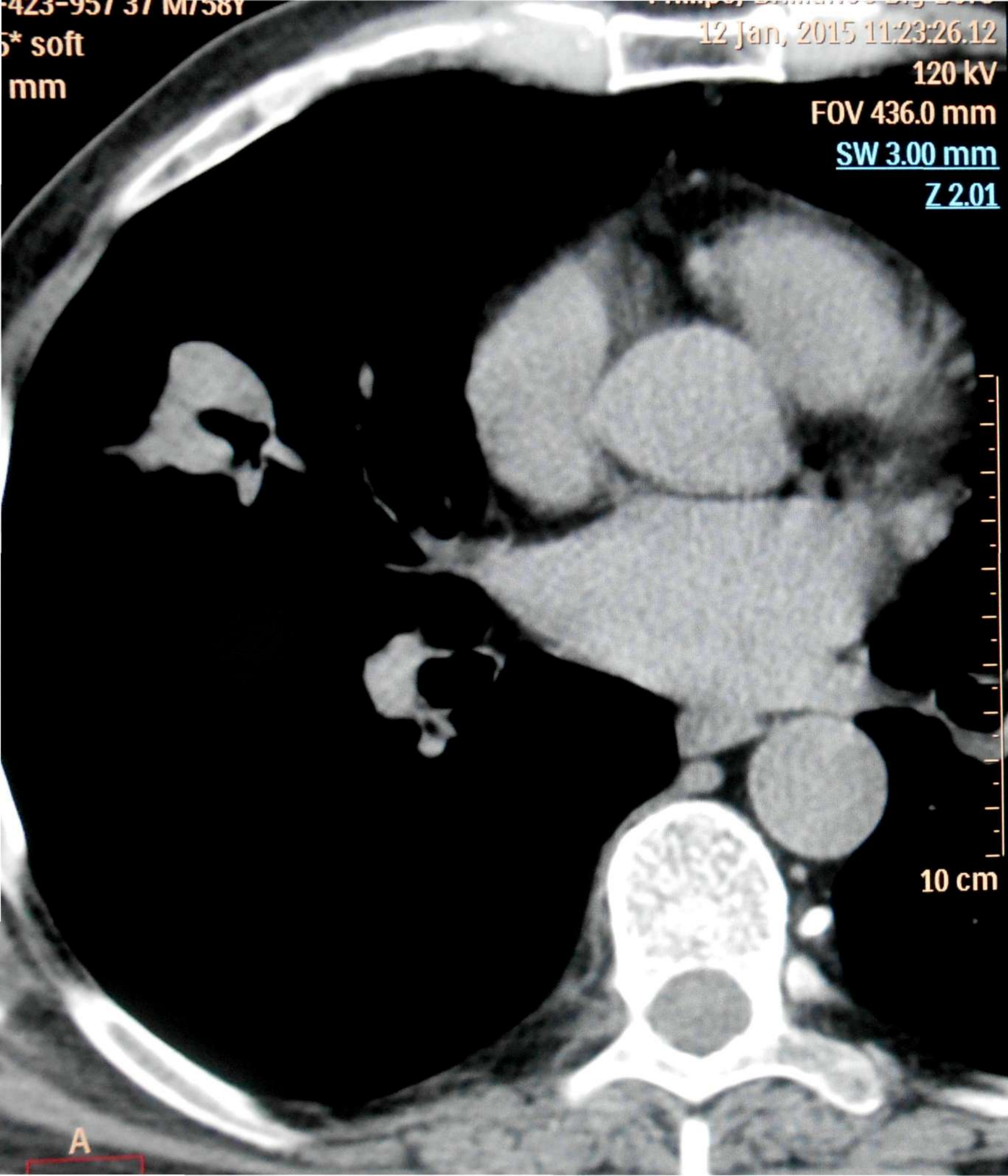
12 Jan, 2015 11:23:26.12

120 kV

FOV 436.0 mm

SW 3.00 mm

Z 2.01

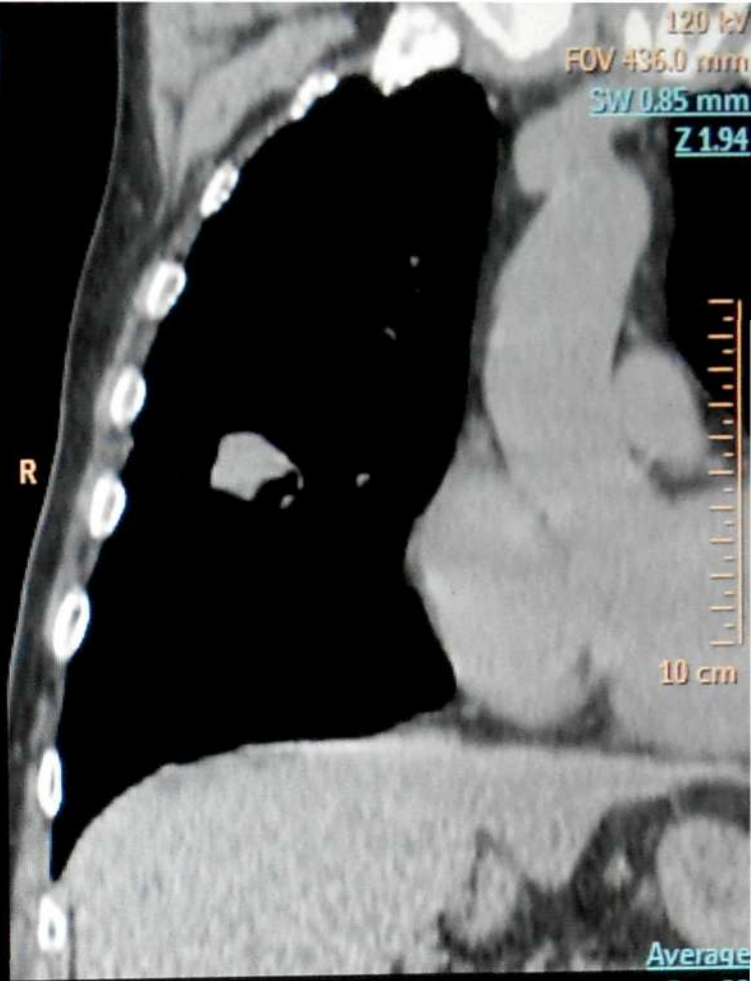


120 kV

FOV 436.0 mm

SW 0.85 mm

Z 1.94



Average

C 22

W 391

F

STVETKOV NM

060-423-957 37 M/58Y

2 soft

Philips, Brilliance Big Bore

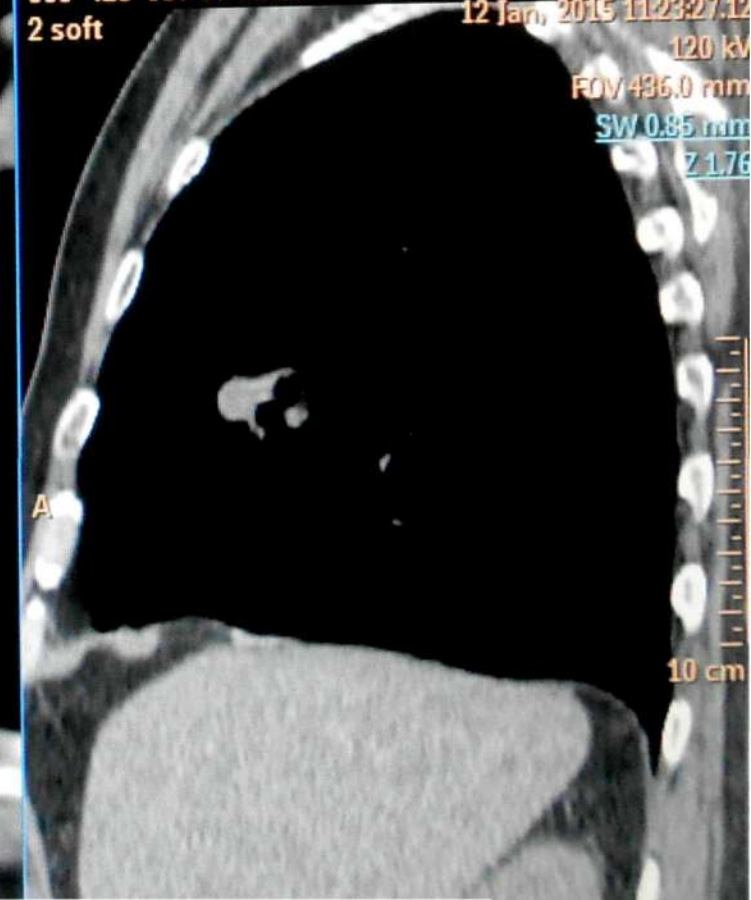
12 Jan, 2015 11:23:27.12

120 kV

FOV 436.0 mm

SW 0.85 mm

Z 1.76



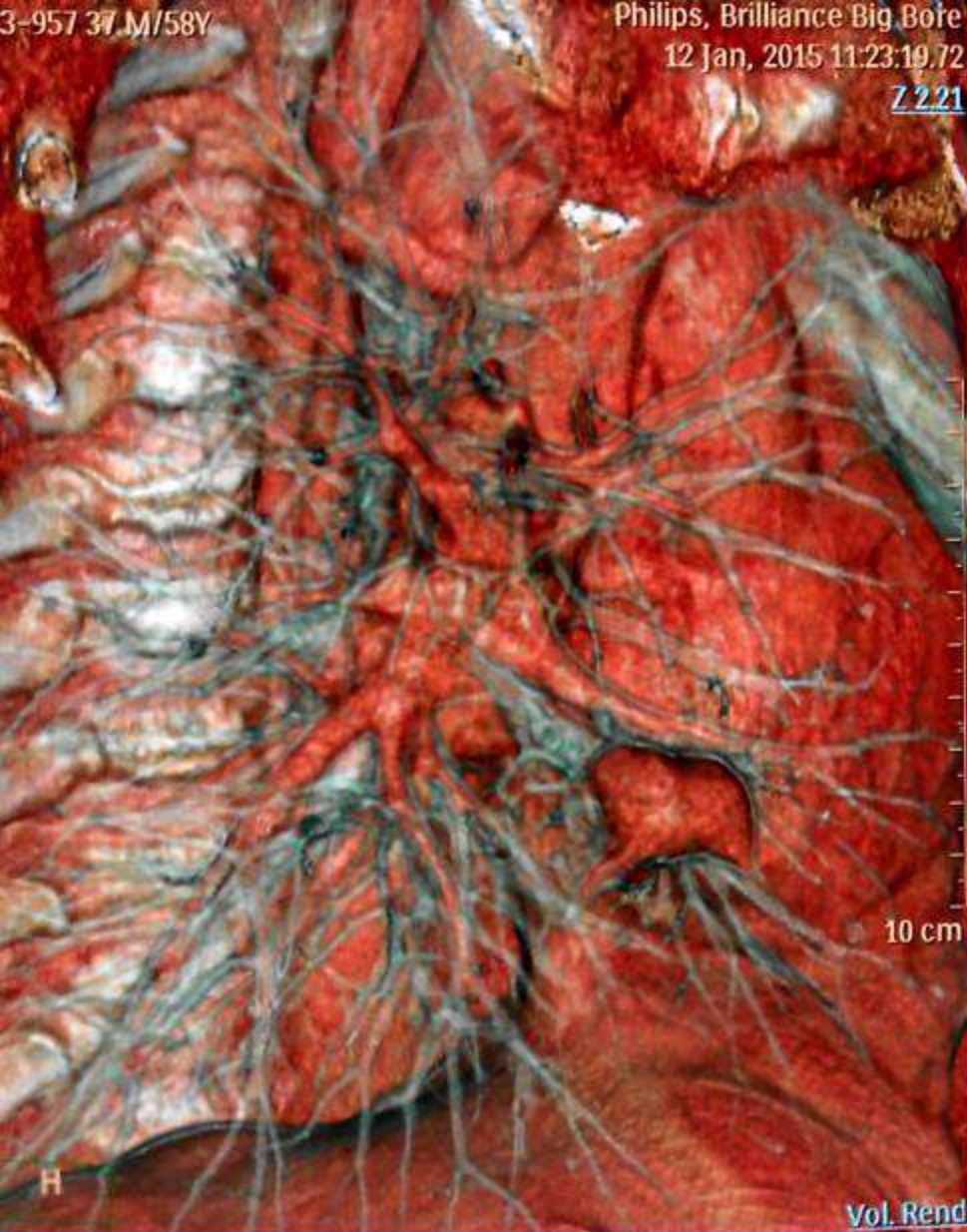
A

3-957 37.M/58Y

Philips, Brilliance Big Bore

12 Jan, 2015 11:23:19.72

7.221



H

10 cm

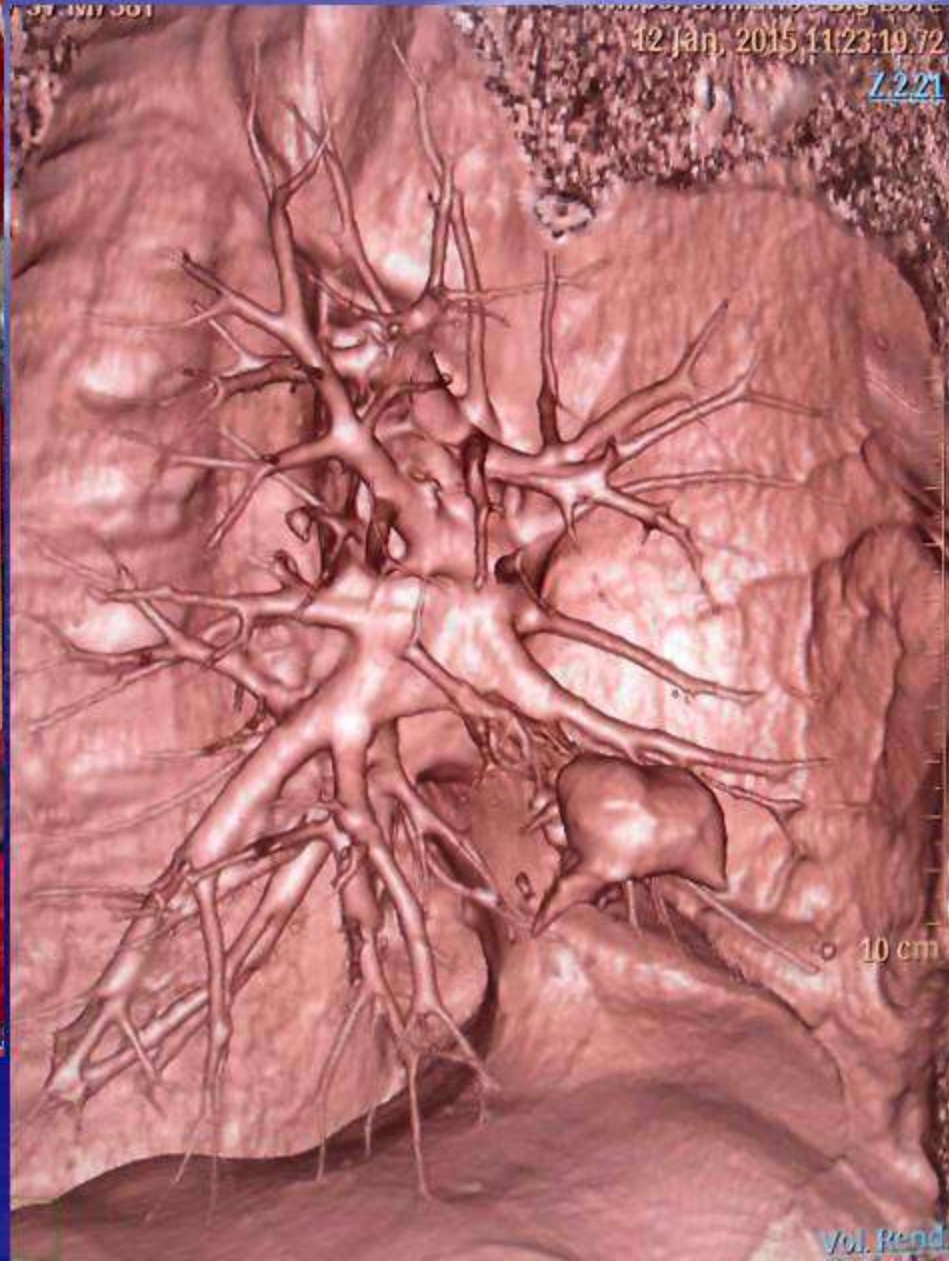
Vol. Rend.

3-957 37.M/58Y

Philips, Brilliance Big Bore

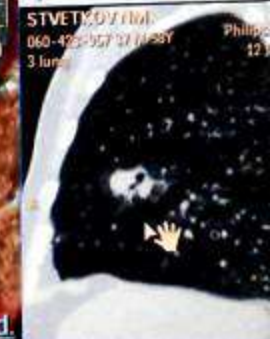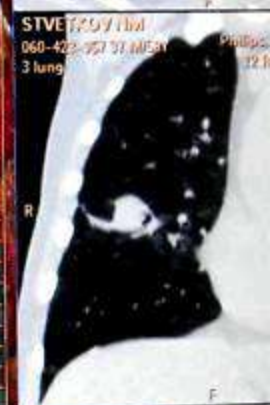
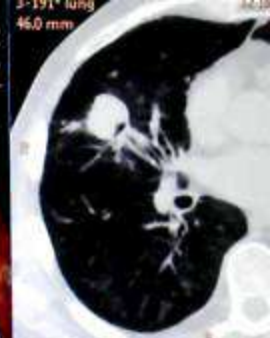
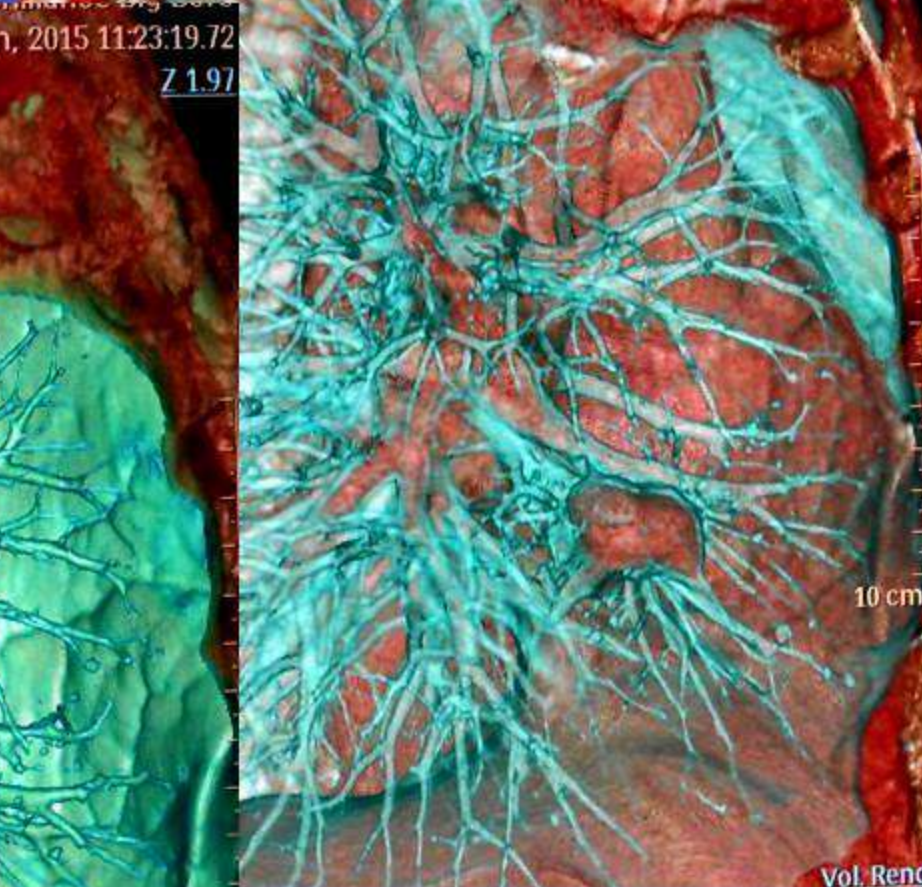
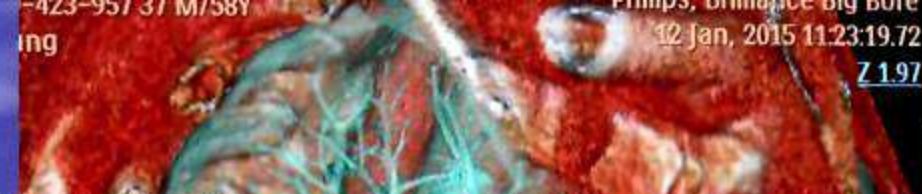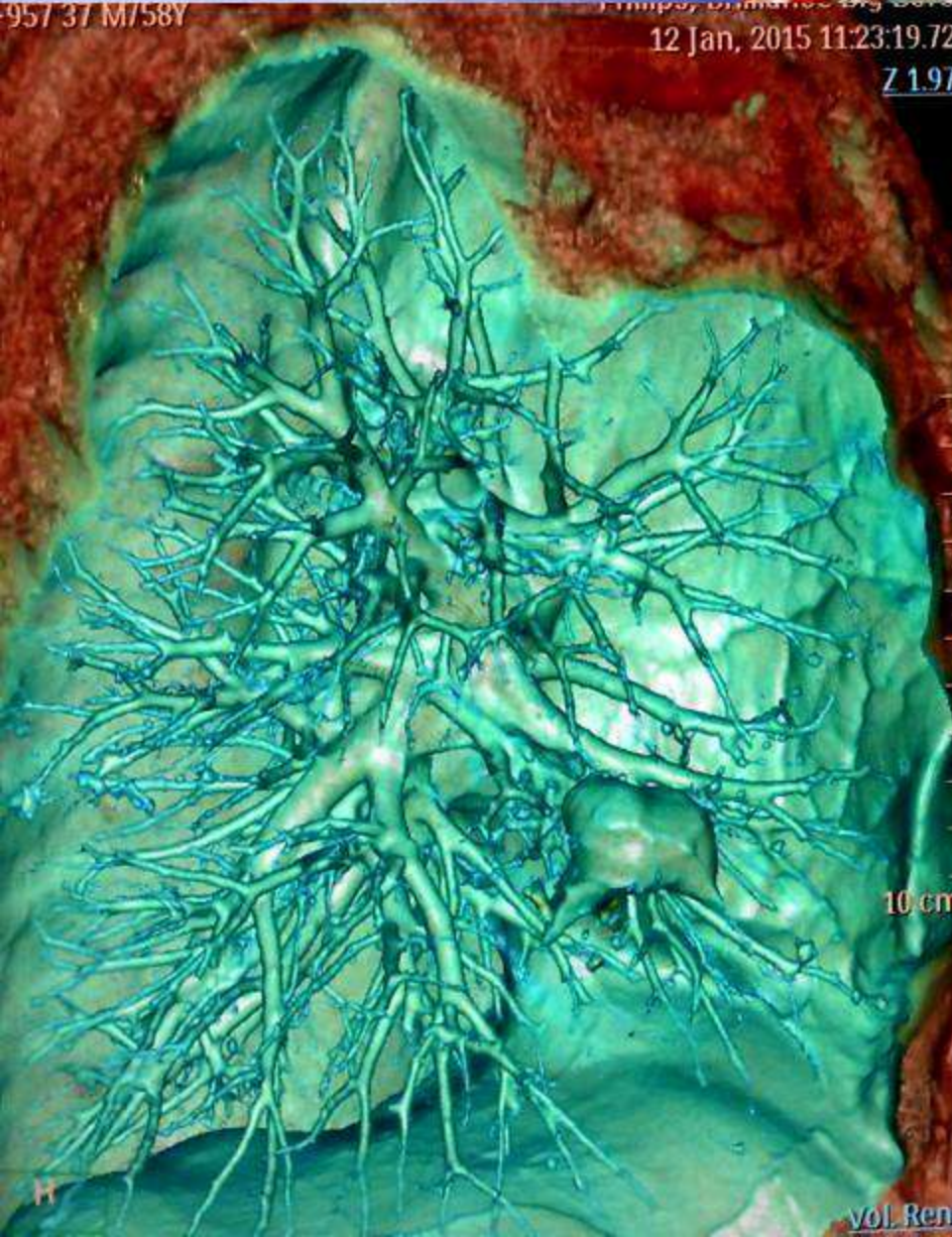
12 Jan, 2015 11:23:19.72

7.221



10 cm

Vol. Rend.



060-423-957 31 M/58Y
ing
Philips, Brilliance Big bore
12 Jan, 2015 11:23:19.72
Z 1.97

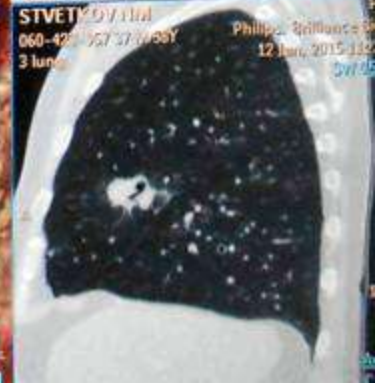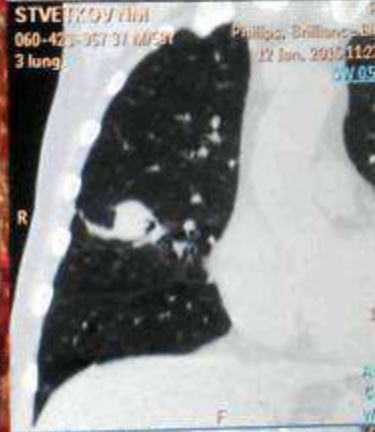
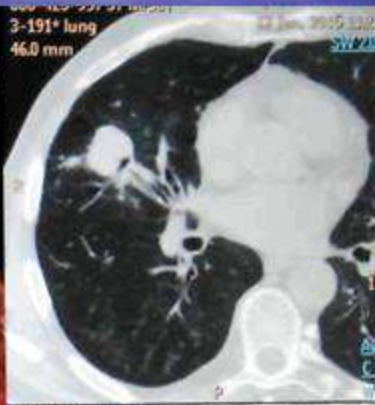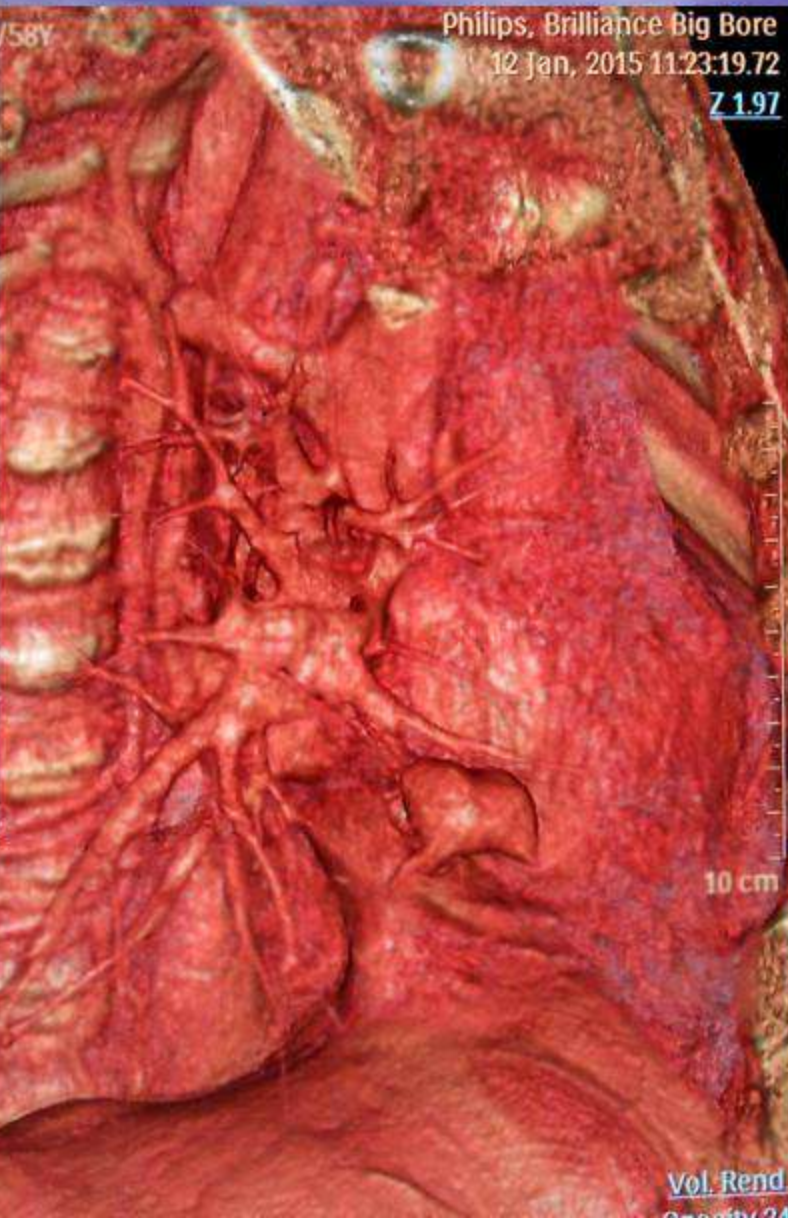
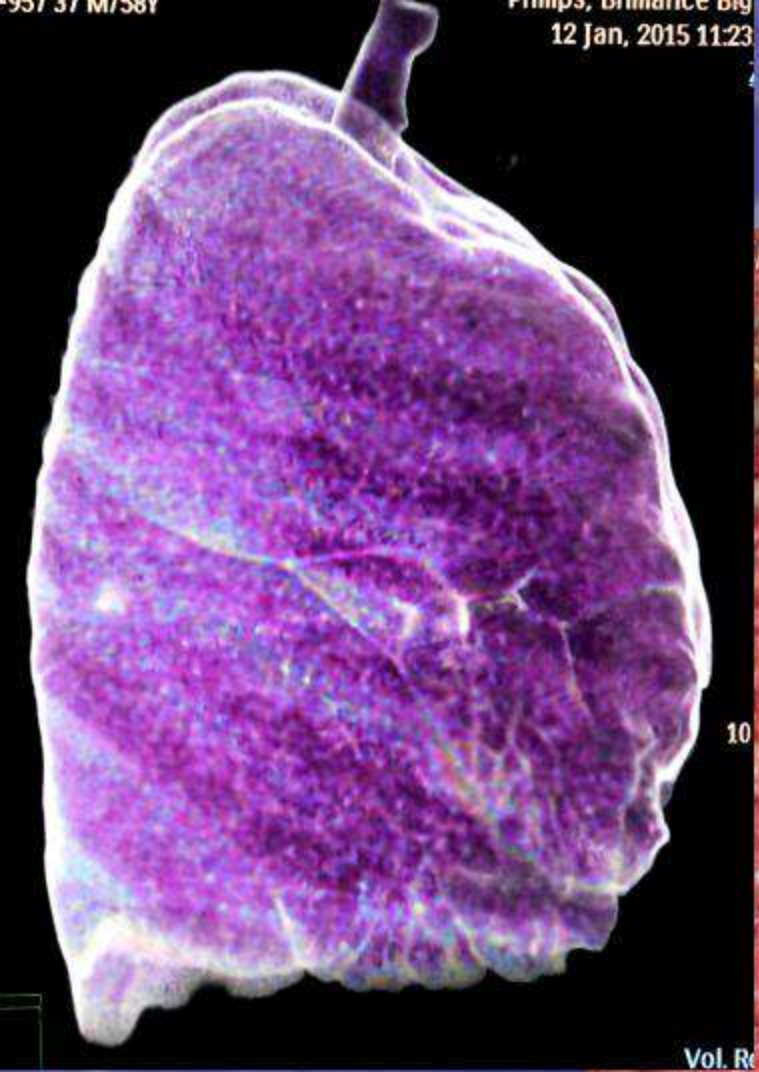060-423-957 31 M/58Y
12 Jan, 2015 11:23:19.72
Z 1.97

STVETSOV (M)
060-423-957 31 M/58Y
3 lung
Philips
12 Jan

STVETSOV (M)
060-423-957 31 M/58Y
3 lung
Philips
12 Jan

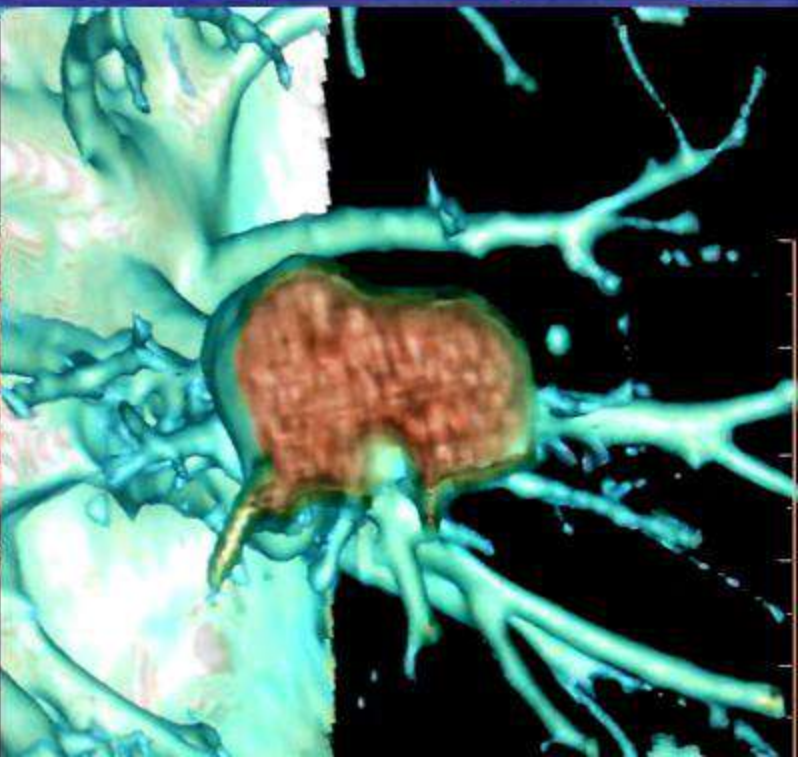
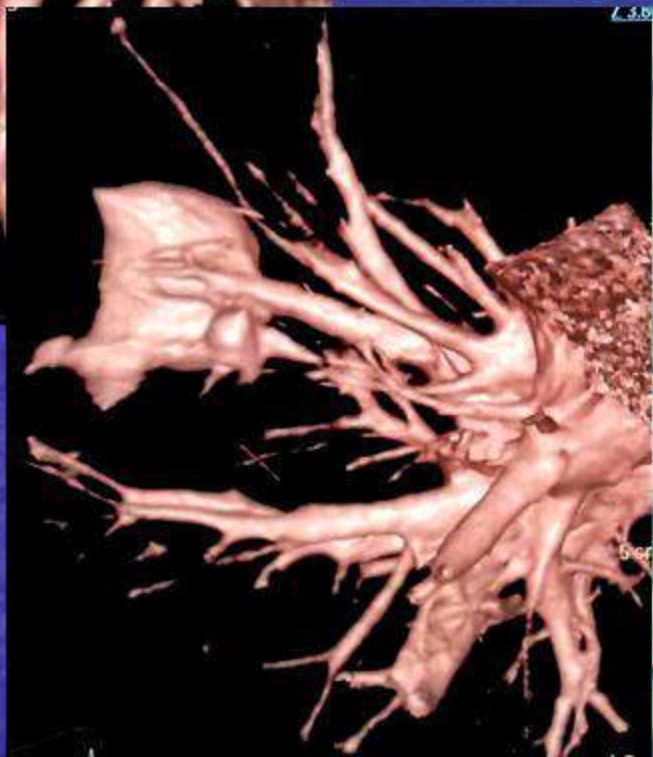
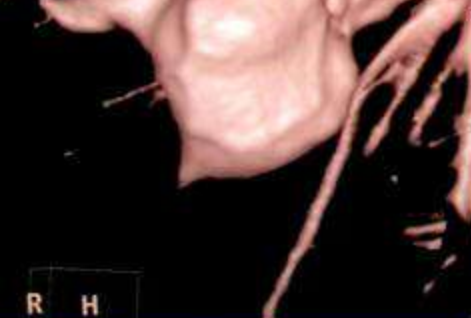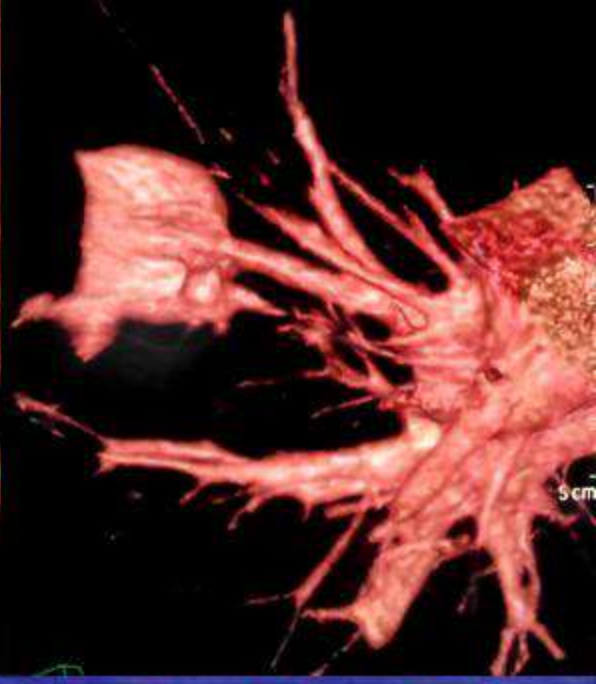
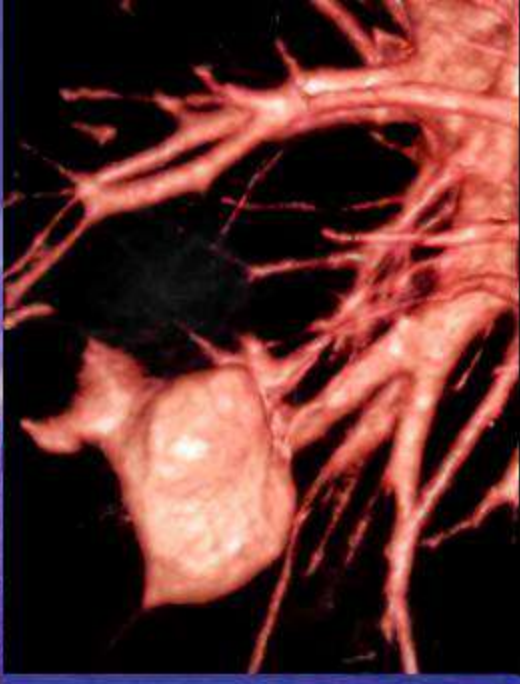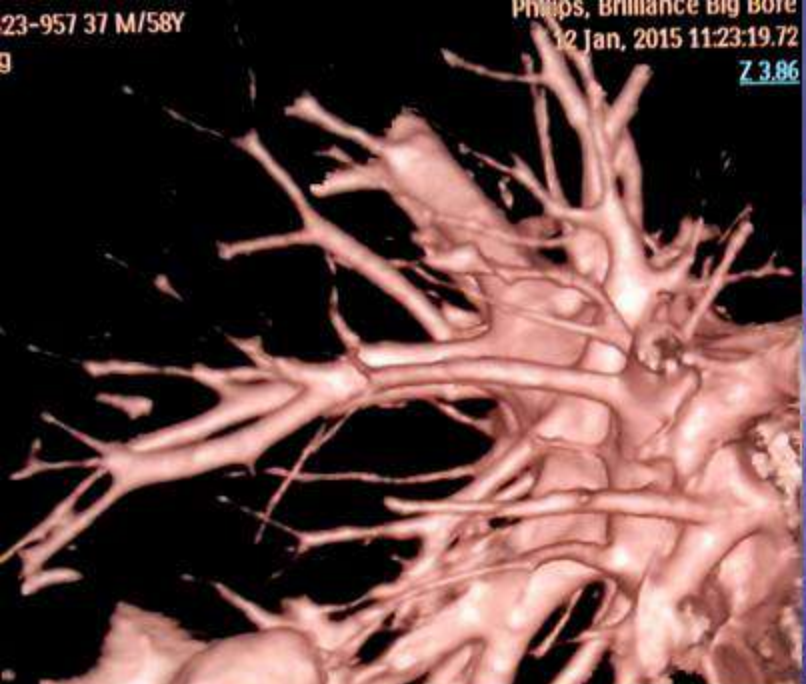
Vol. Rend.

Vol. Rend.



23-957 37 M/58Y
g

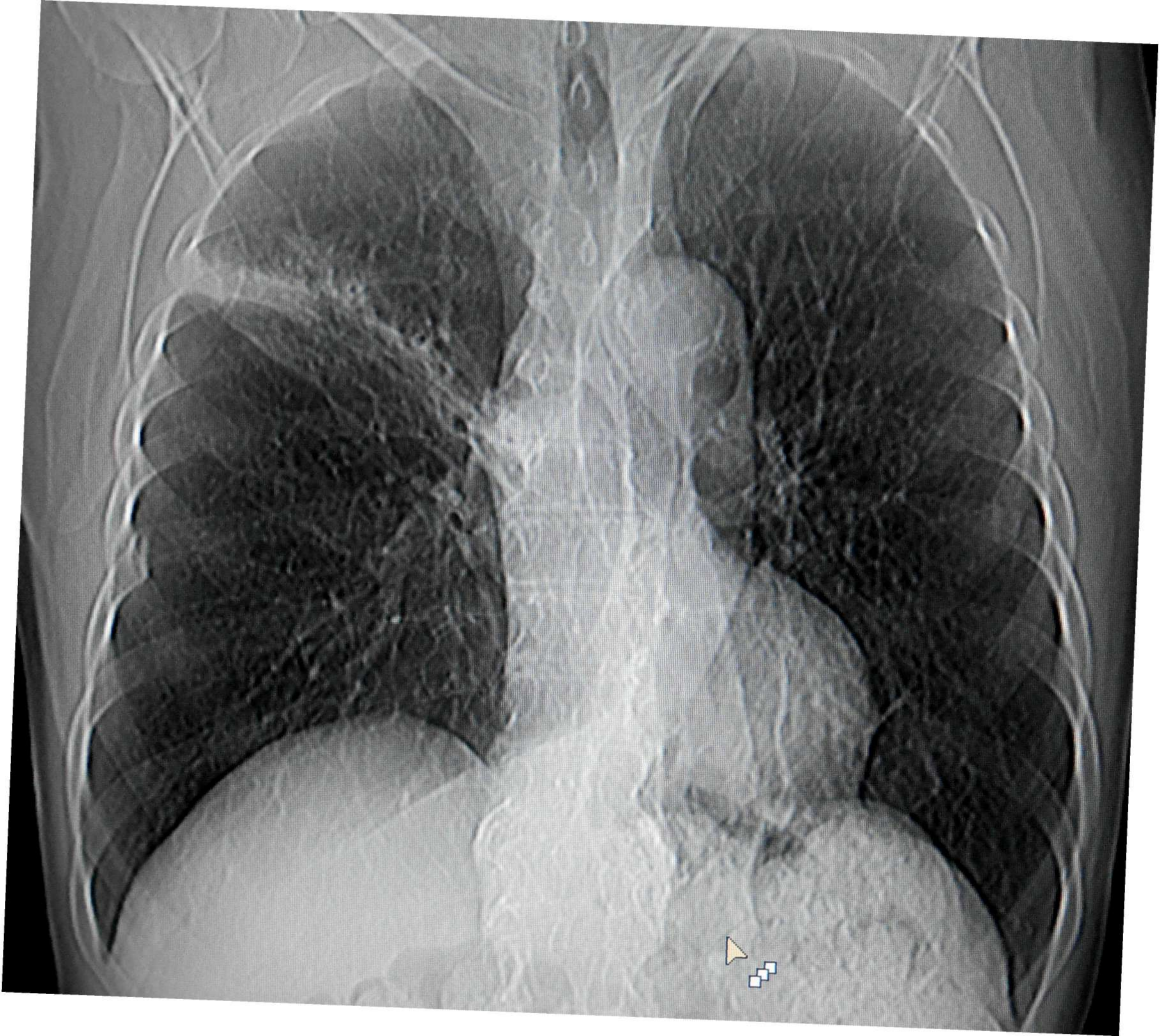Philips, Brilliance Big Bore
12 Jan, 2015 11:23:19.72
Z 3.86



R H

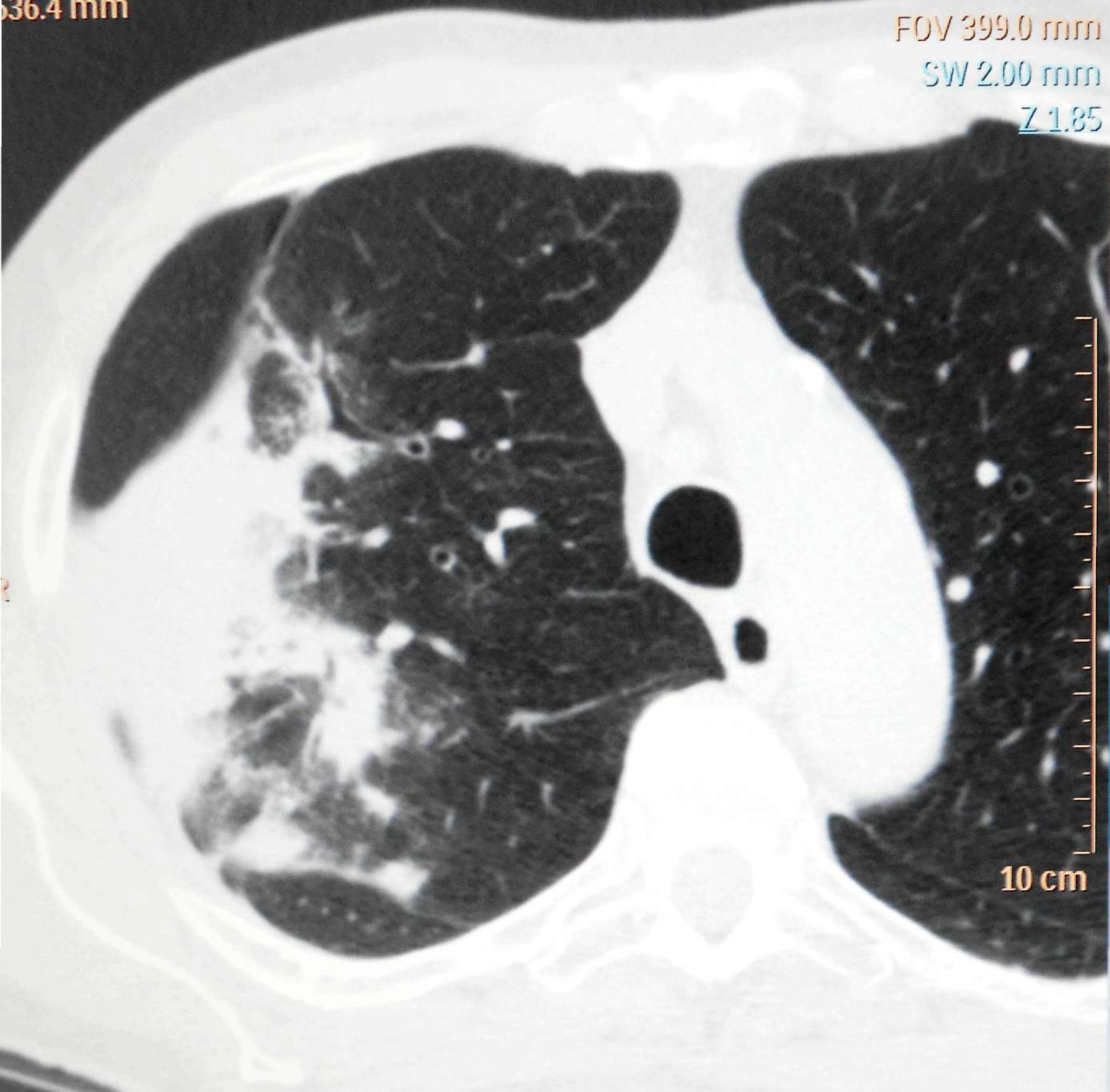
Правосторонняя
хроническая верхнедолевая
пневмония (пневмосклероз, карнификация),
ограниченный (осумкованный)
пневмоторакс.

МСКТ. Наблюдение из практики.

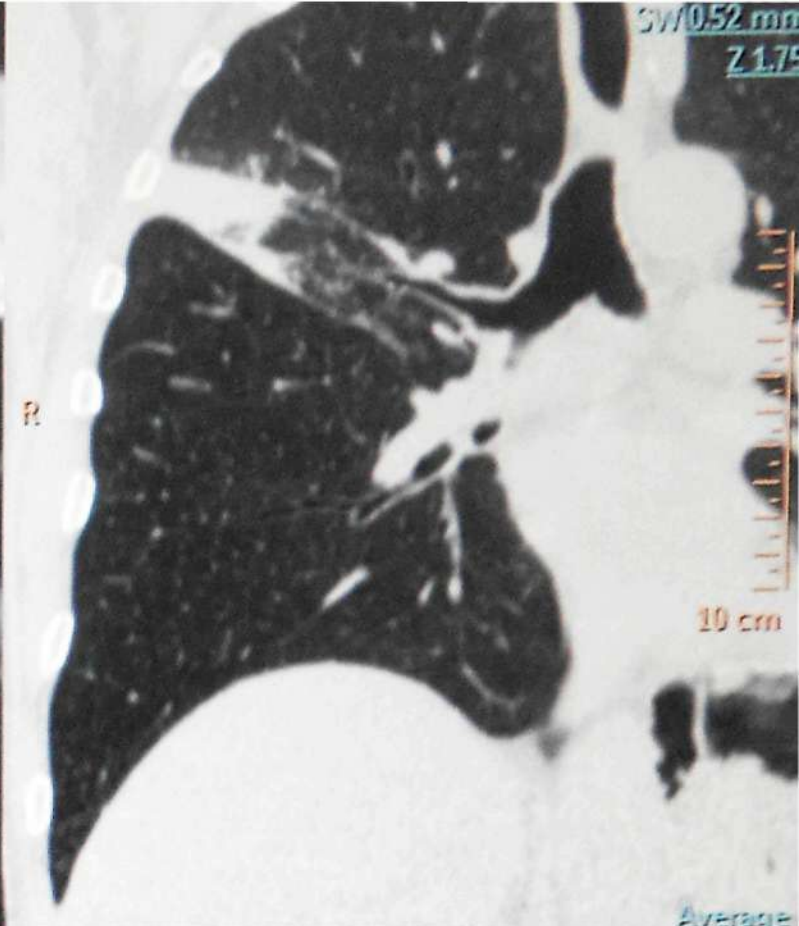

124* lung
36.4 mm

120 kV
FOV 399.0 mm
SW 2.00 mm
Z 1.85



A



SW 0.52 mm
Z 1.75

10 cm

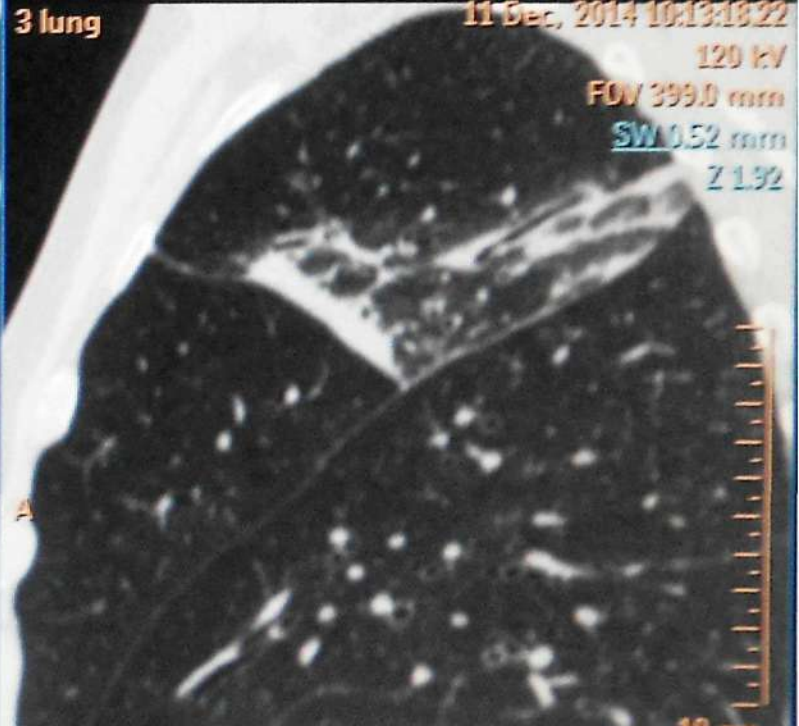
Average
C -500
W 1500

MOLOTOVN K
069-789-086 49 M/68Y
3 lung

Philips, Brilliance Big Bore
11 Dec, 2014 10:13:18:22

PMSTL

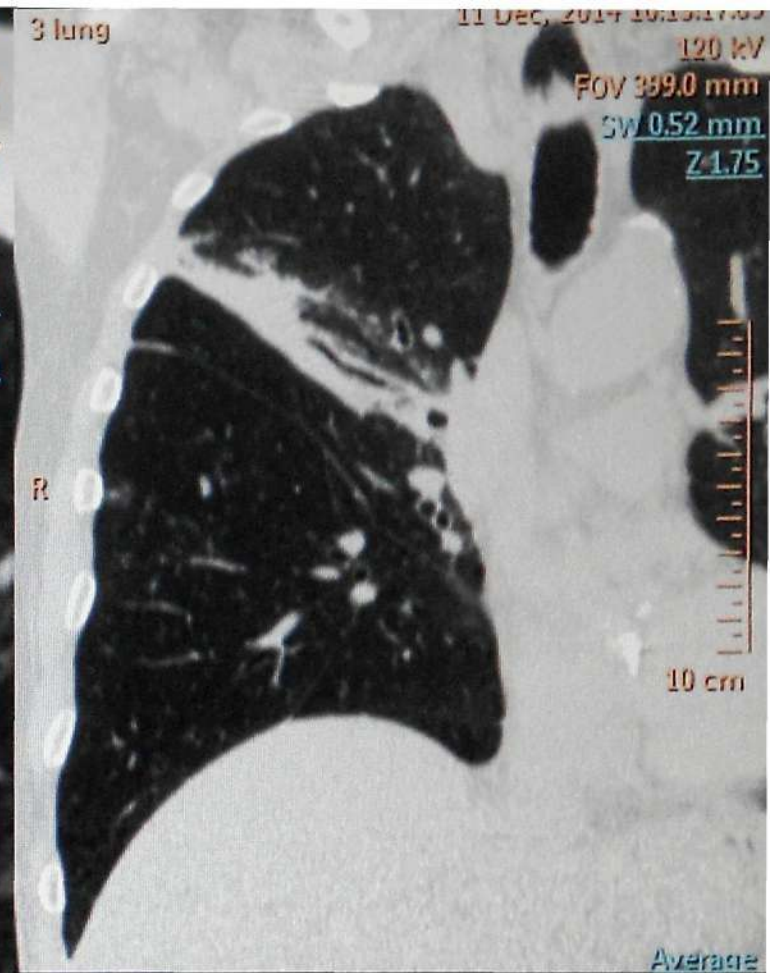
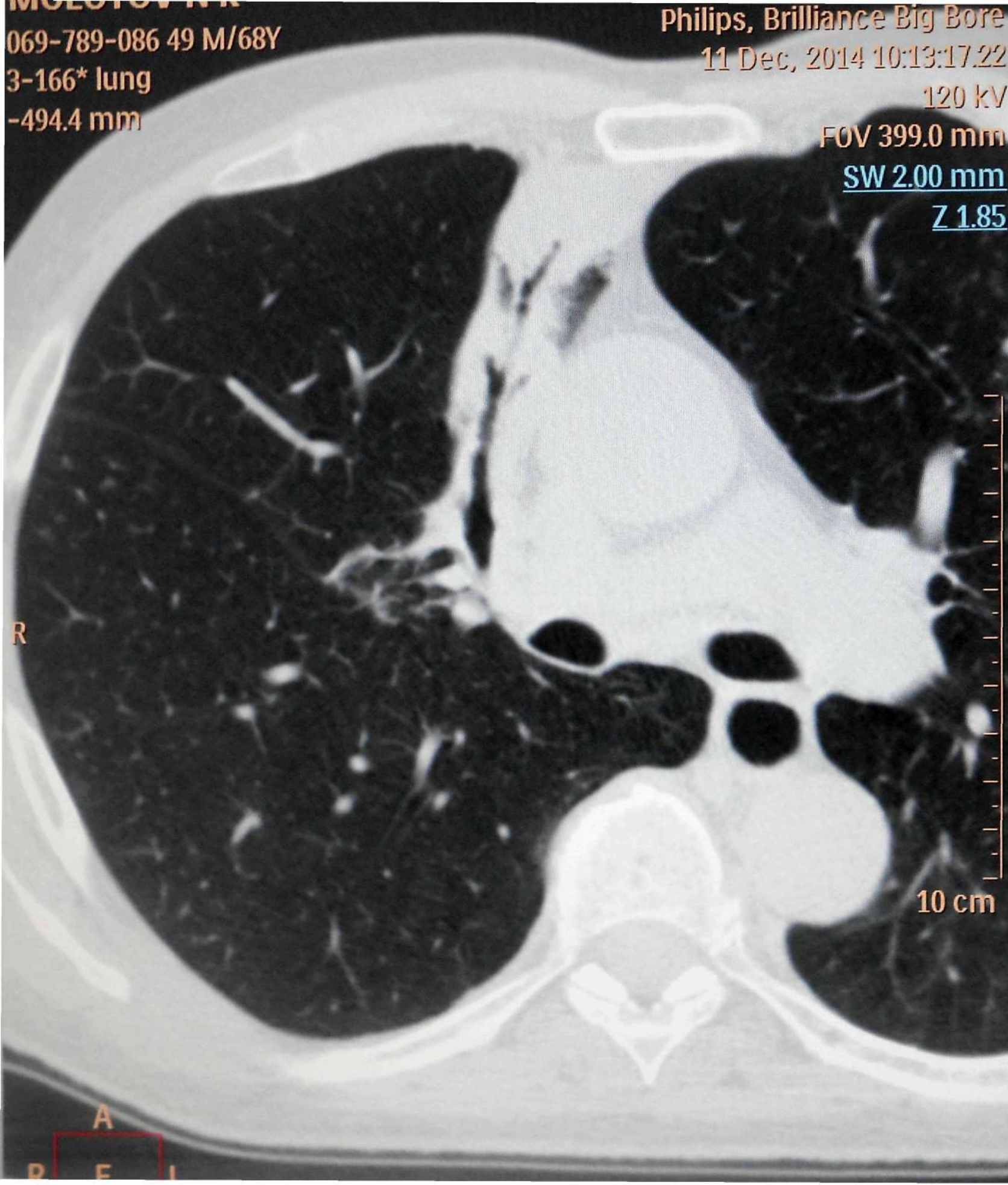
120 kV
FOV 399.0 mm
SW 0.52 mm
Z 1.92



10 cm

MOLOTOV N K
069-789-086 49 M/68Y
3-166* lung
-494.4 mm

Philips, Brilliance Big Bore
11 Dec, 2014 10:13:17.22
120 kV
FOV 399.0 mm
SW 2.00 mm
Z 1.85



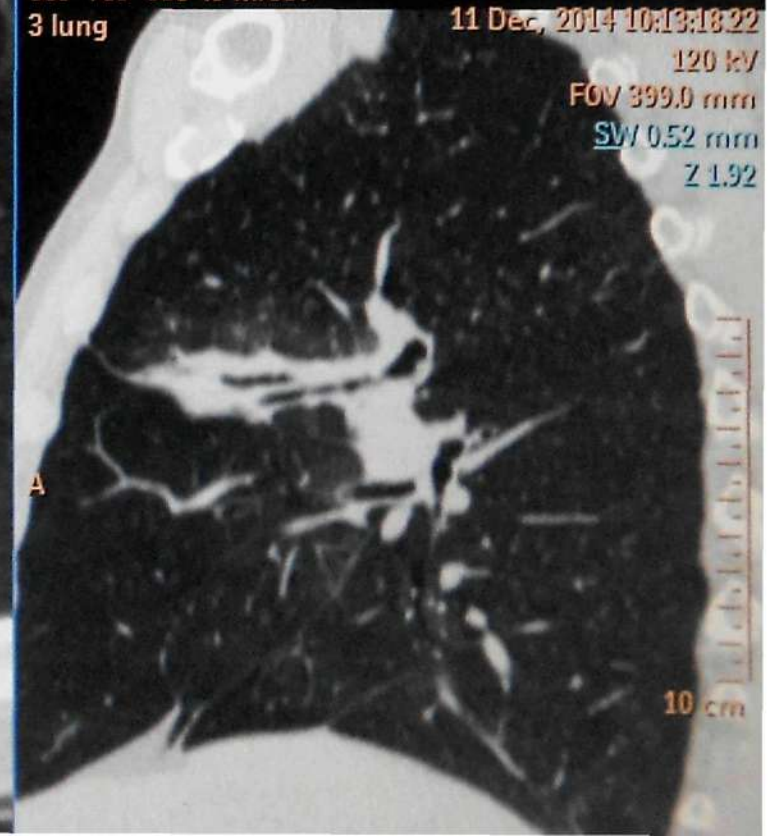
Average
C -500
W 1500

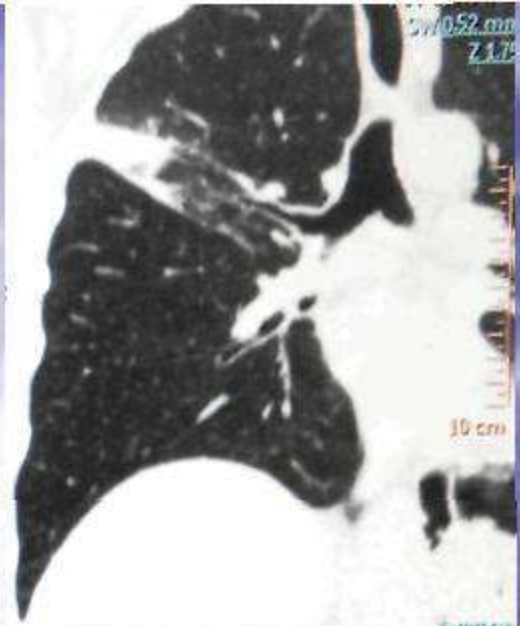MOLOTOV N K
069-789-086 49 M/68Y
3 lung

F

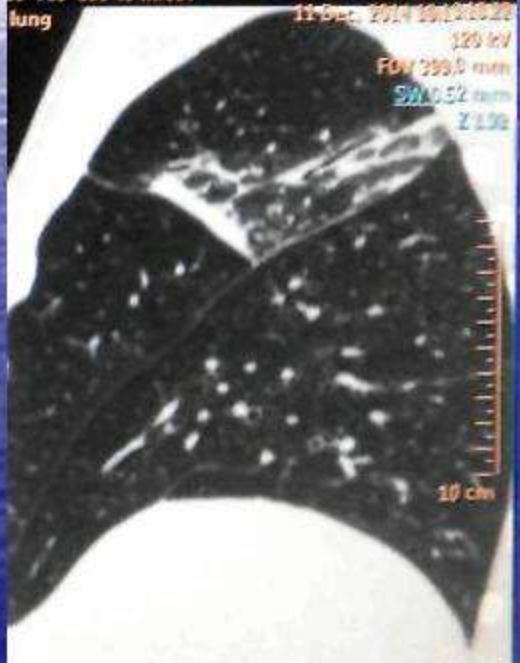
Philips, Brilliance Big Bore
11 Dec, 2014 10:13:18.22

120 kV
FOV 399.0 mm
SW 0.52 mm
Z 1.92

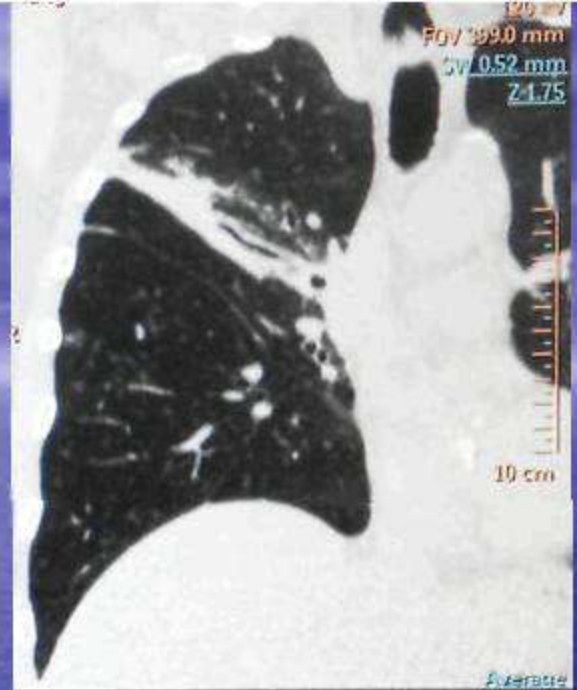




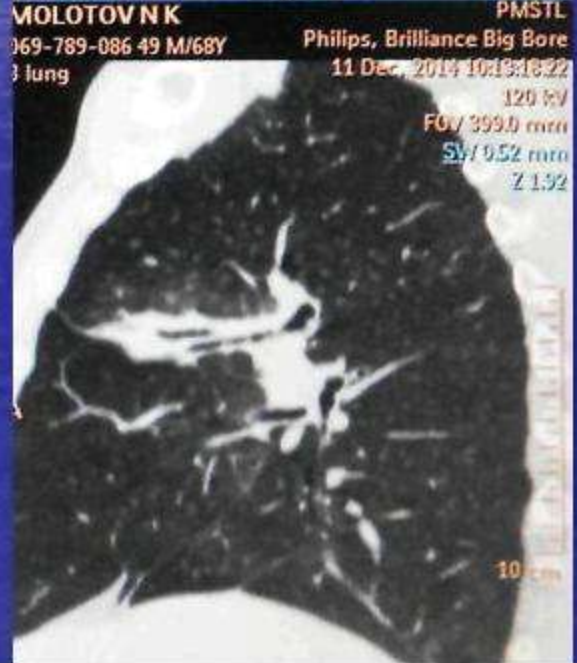MOLOTOV N K
69-789-086 49 M/68Y
lung
F
C -500
W 1500
PMSTL



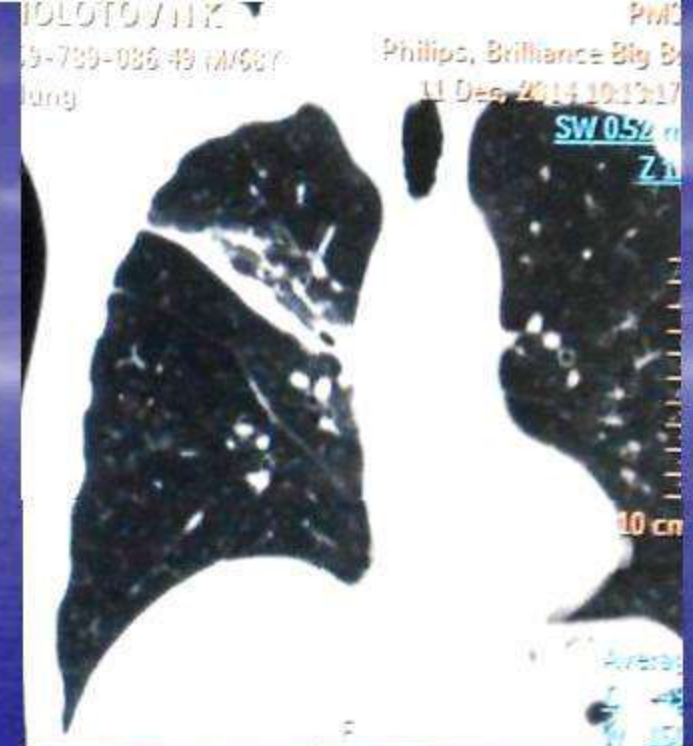MOLOTOV N K
69-789-086 49 M/68Y
lung
F
C -500
W 1500
PMSTL



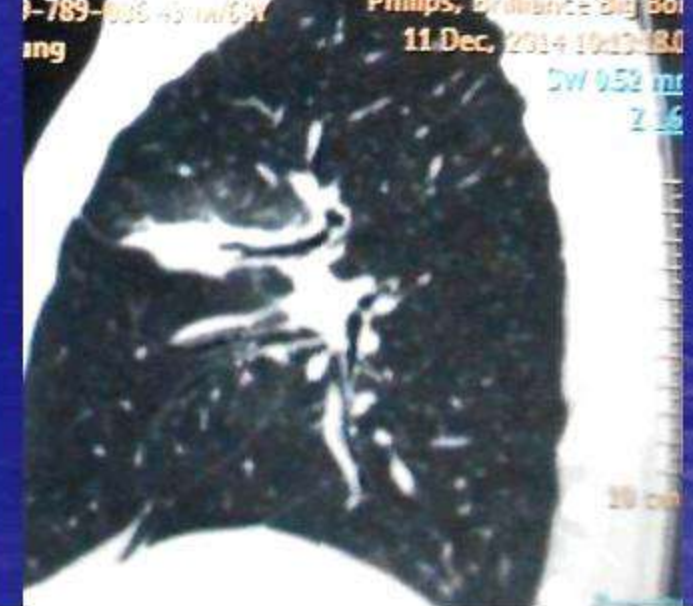
MOLOTOV N K
69-789-086 49 M/68Y
lung
F
C -500
W 1500
PMSTL



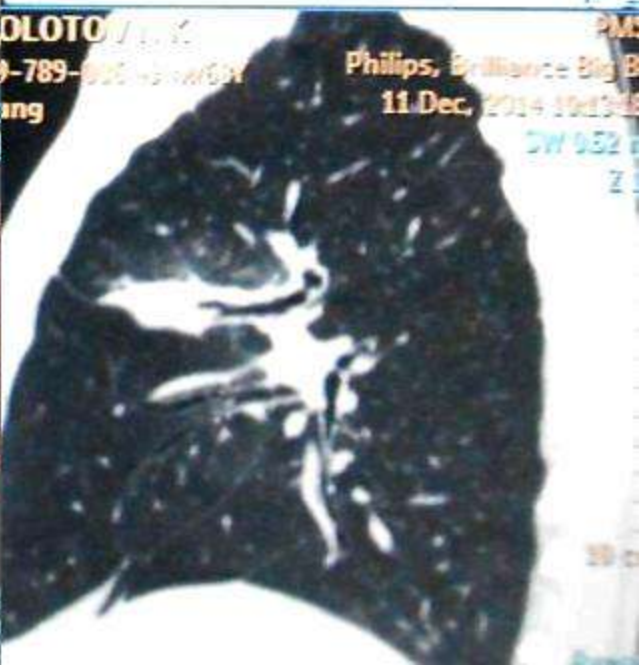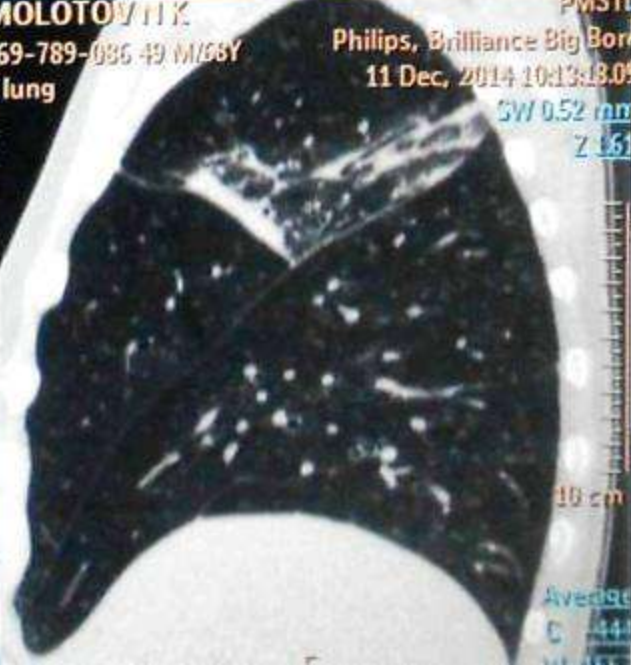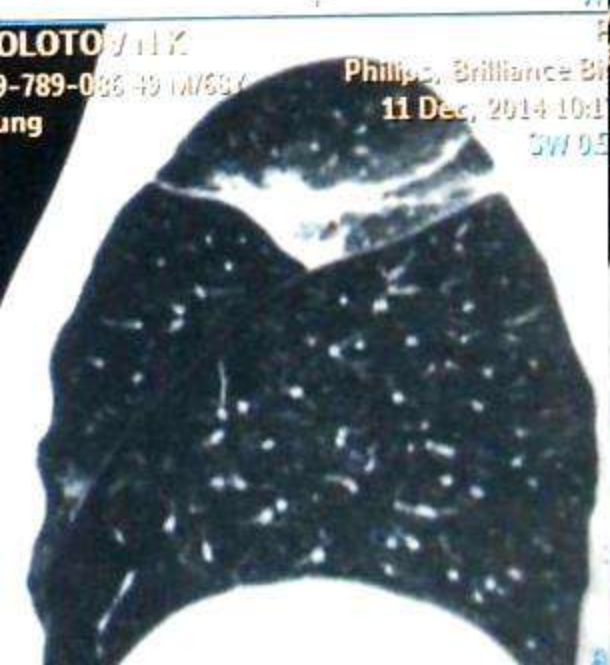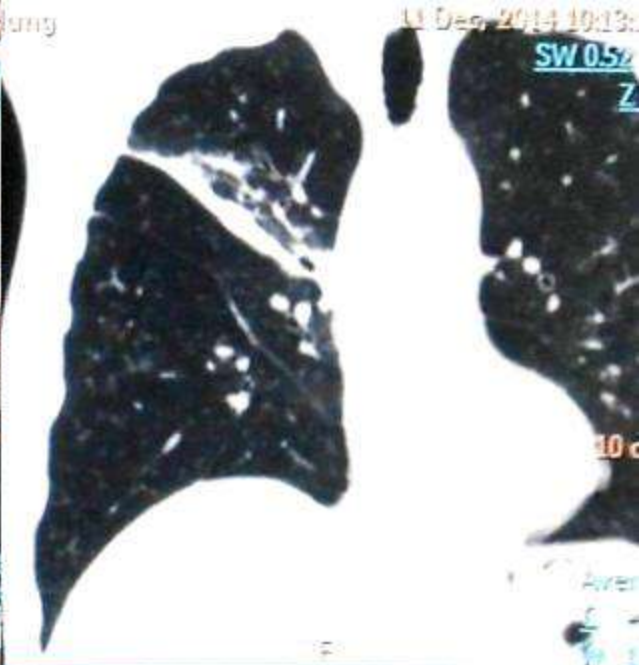
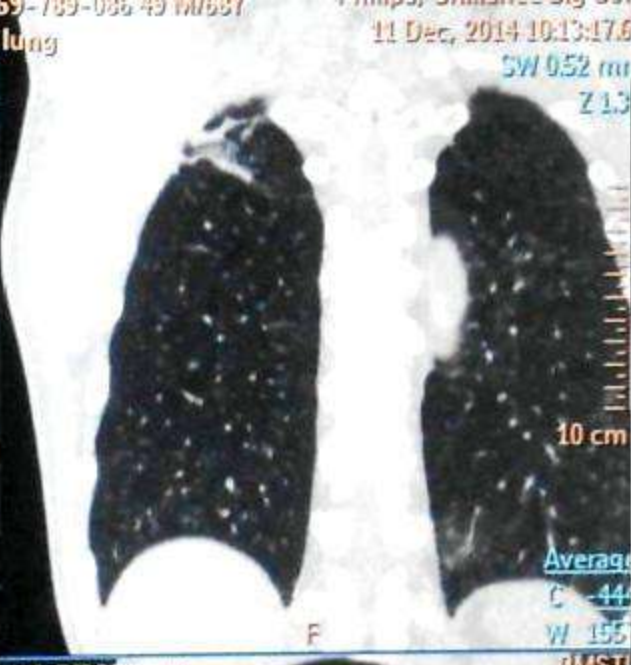
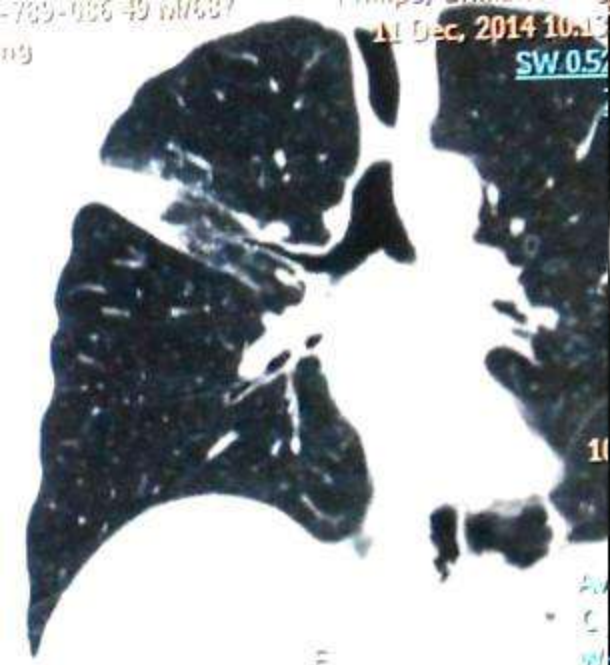
MOLOTOV N K
69-789-086 49 M/68Y
lung
F
C -500
W 1500
PMSTL

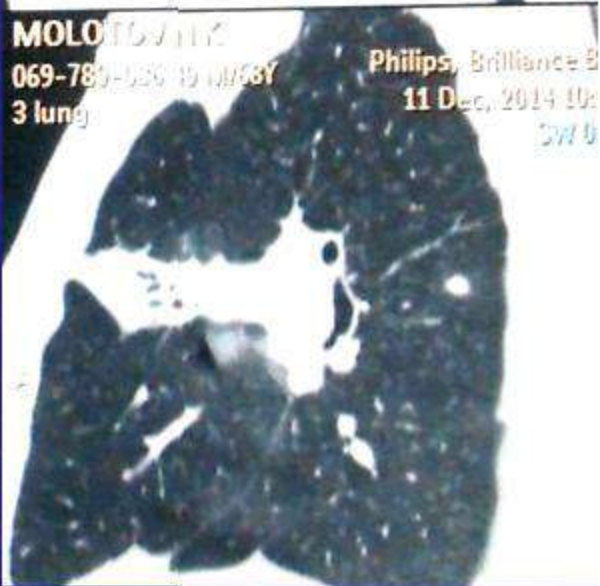
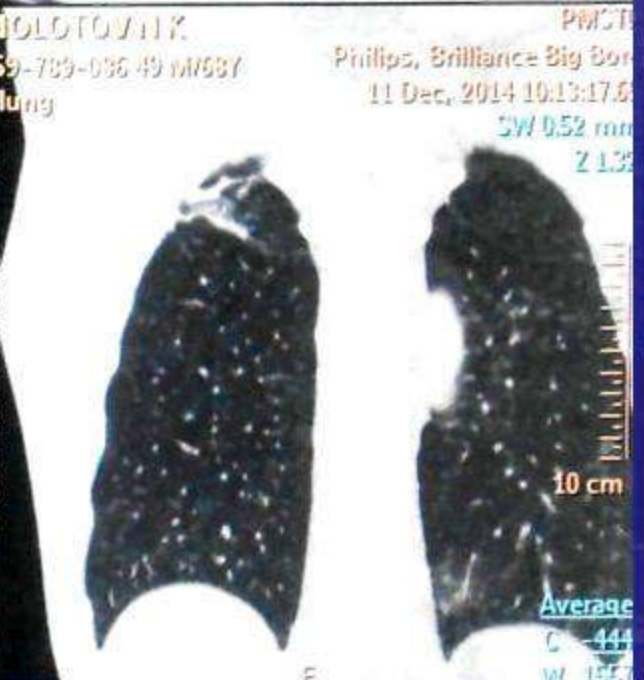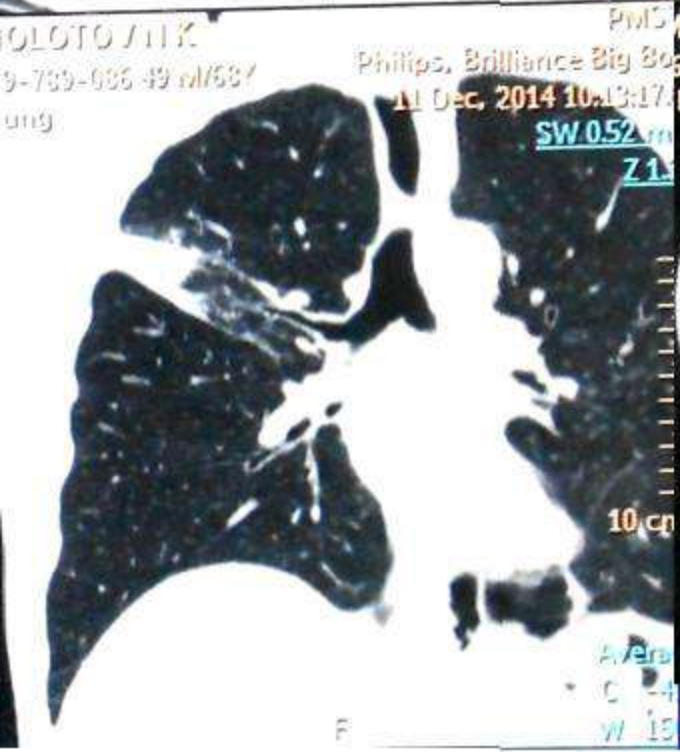
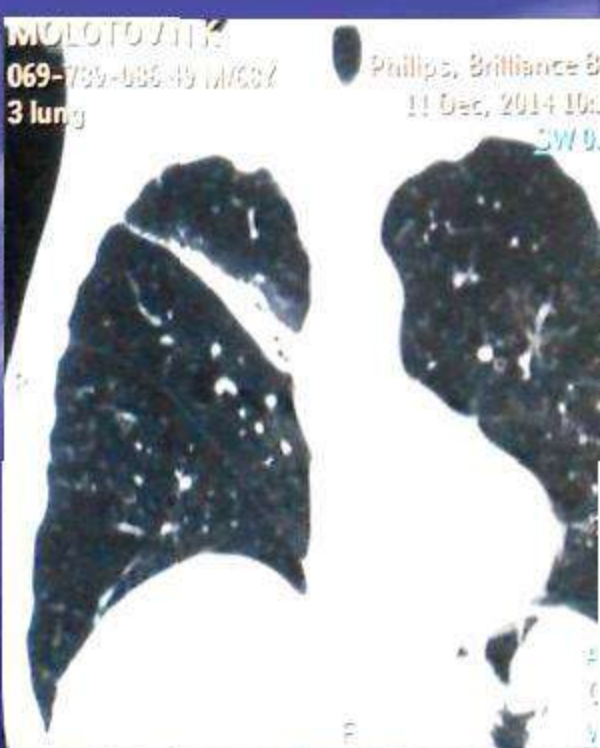
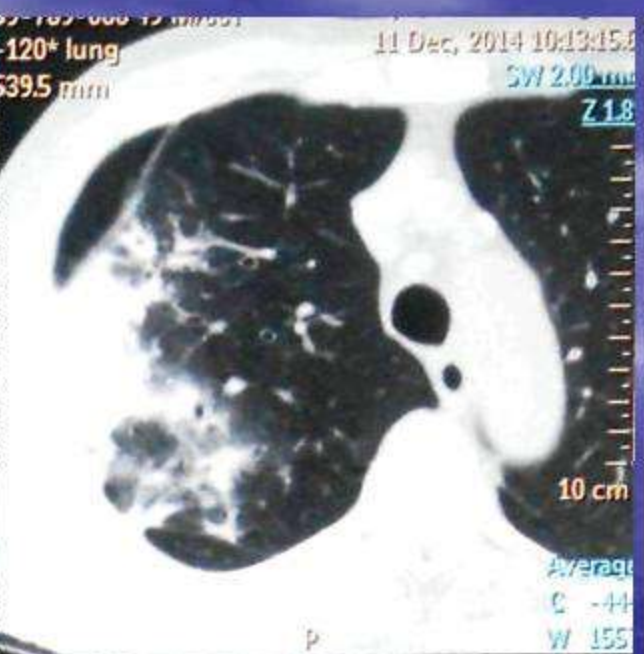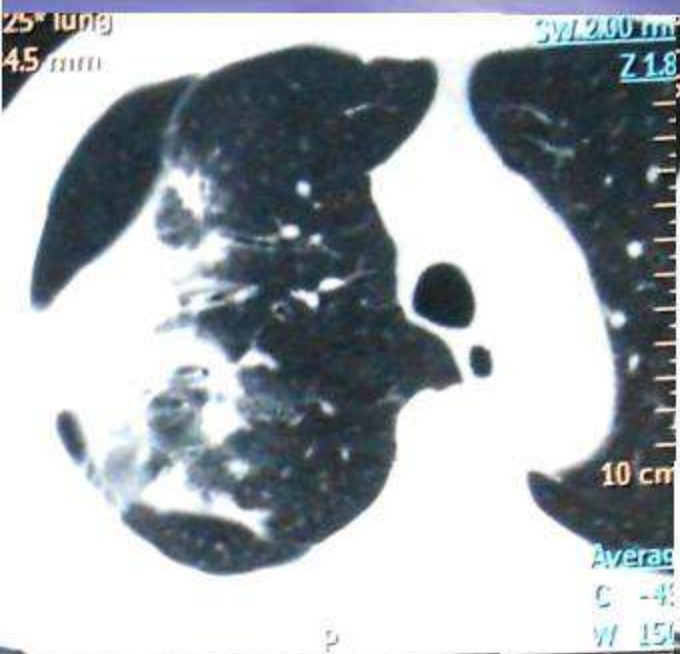


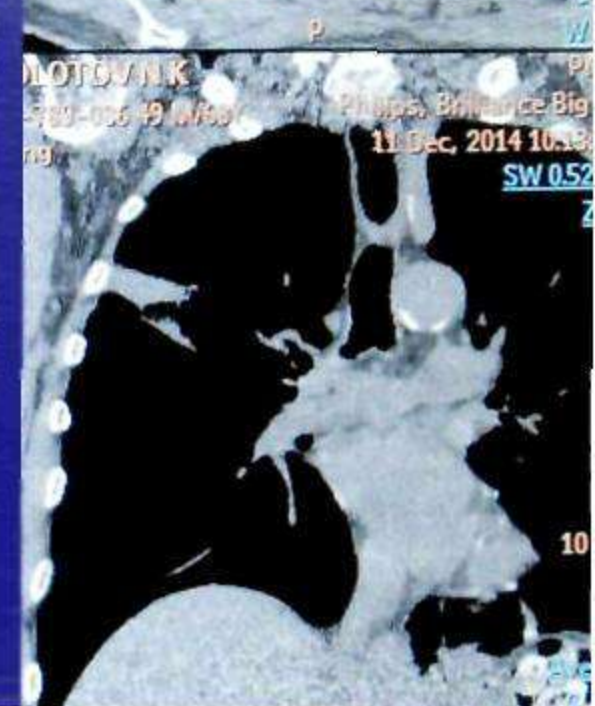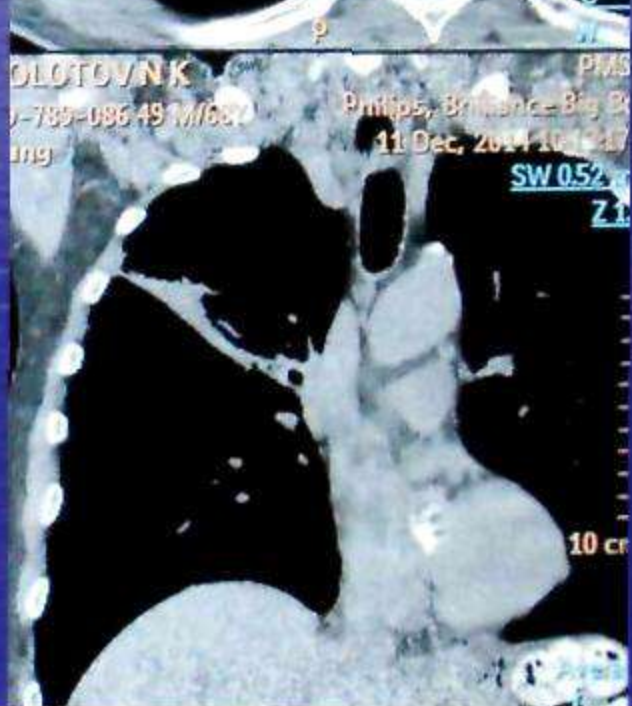
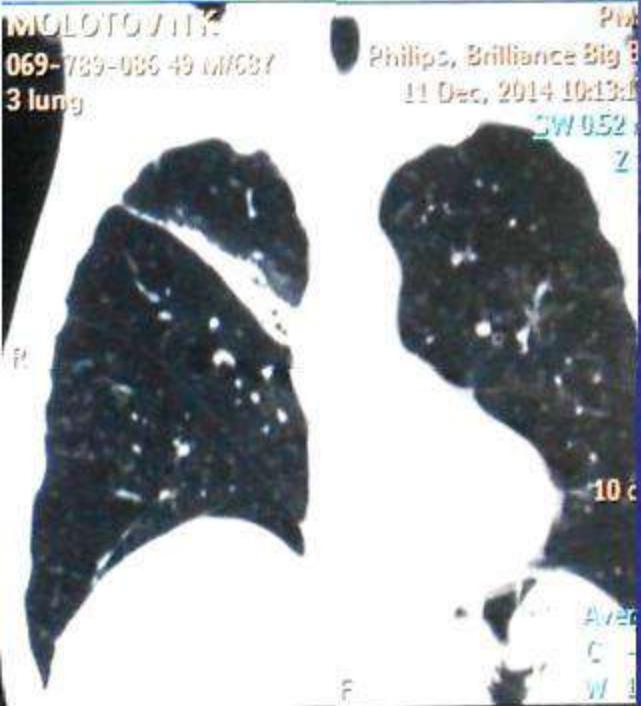
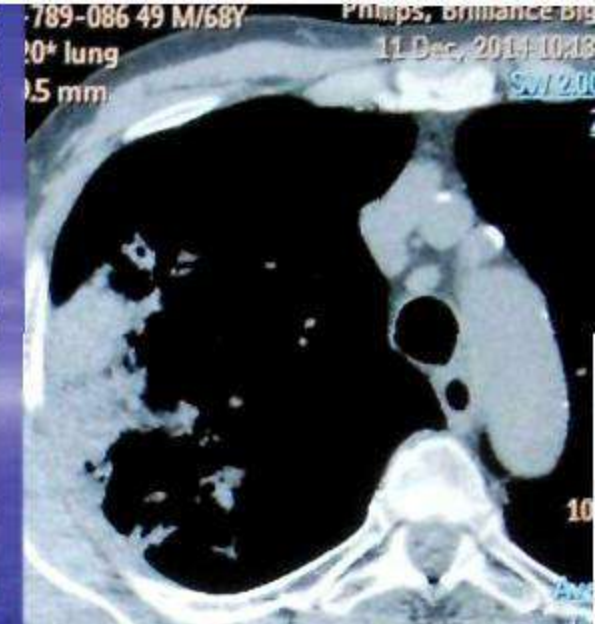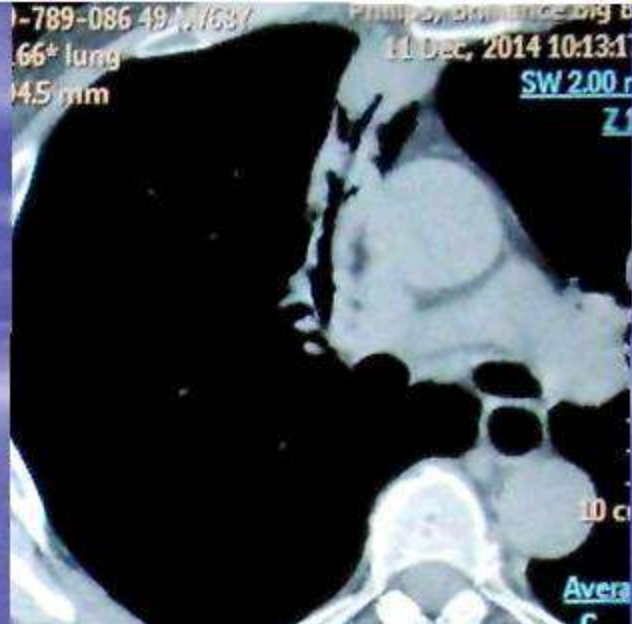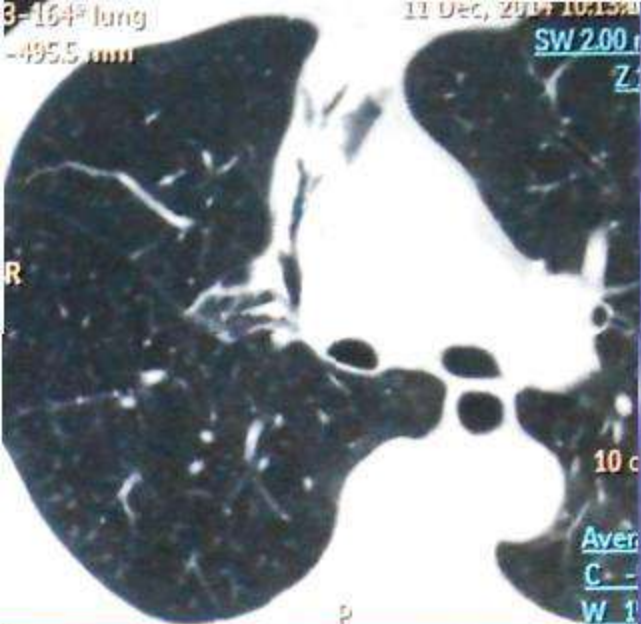
MOLOTOV N K
69-789-086 49 M/68Y
lung
F
C -500
W 1500
PMSTL

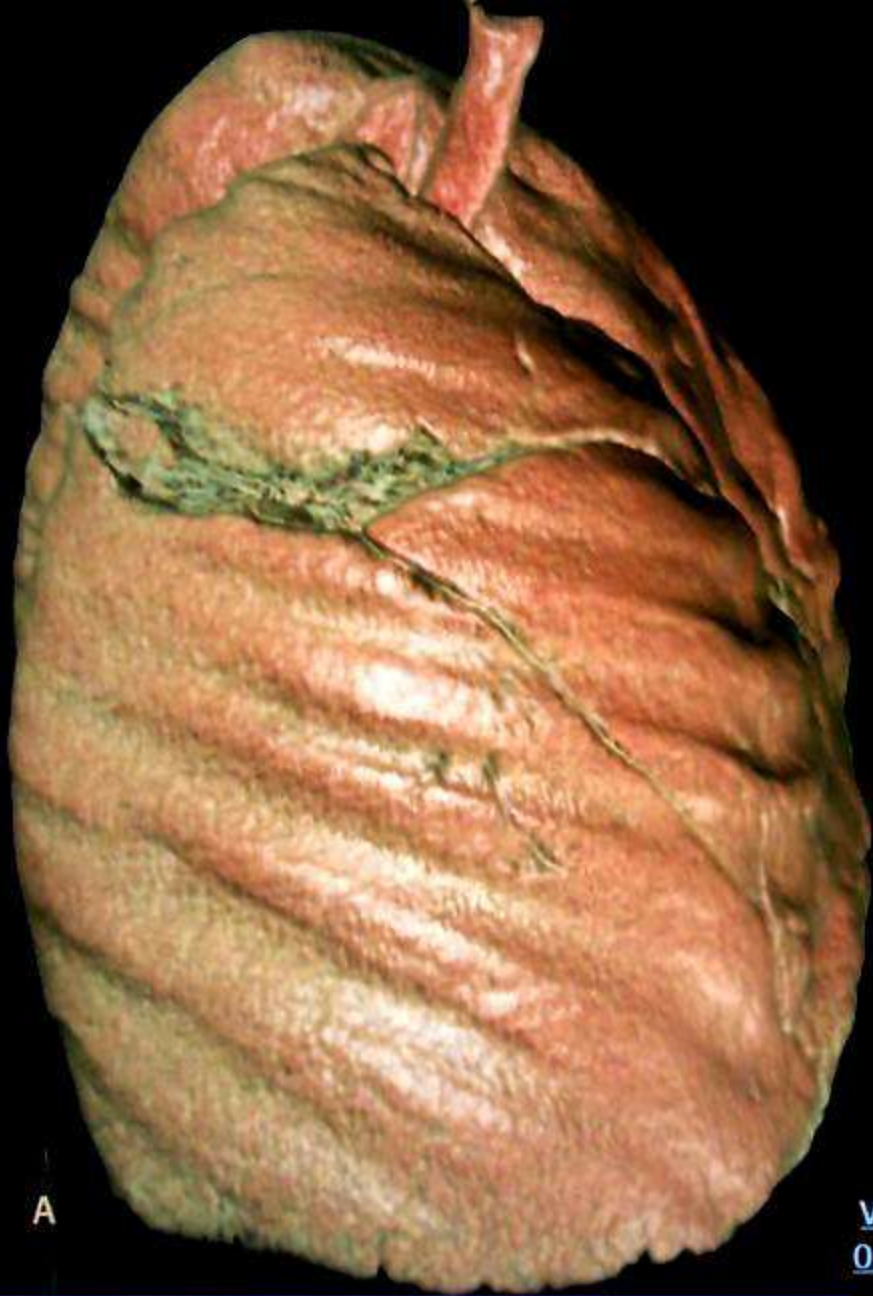

MOLOTOV N K
69-789-086 49 M/68Y
lung
F
C -500
W 1500
PMSTL

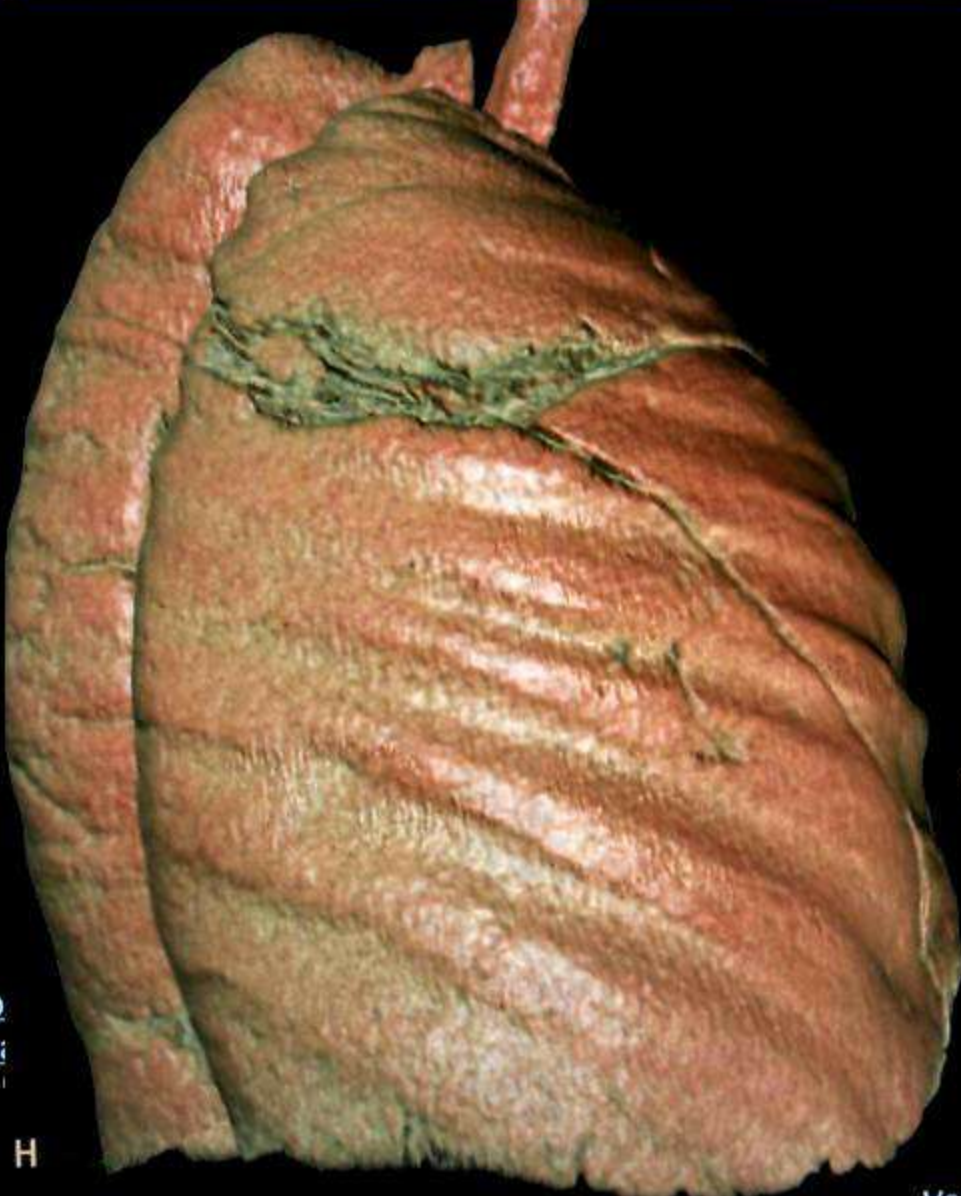







H
R
A

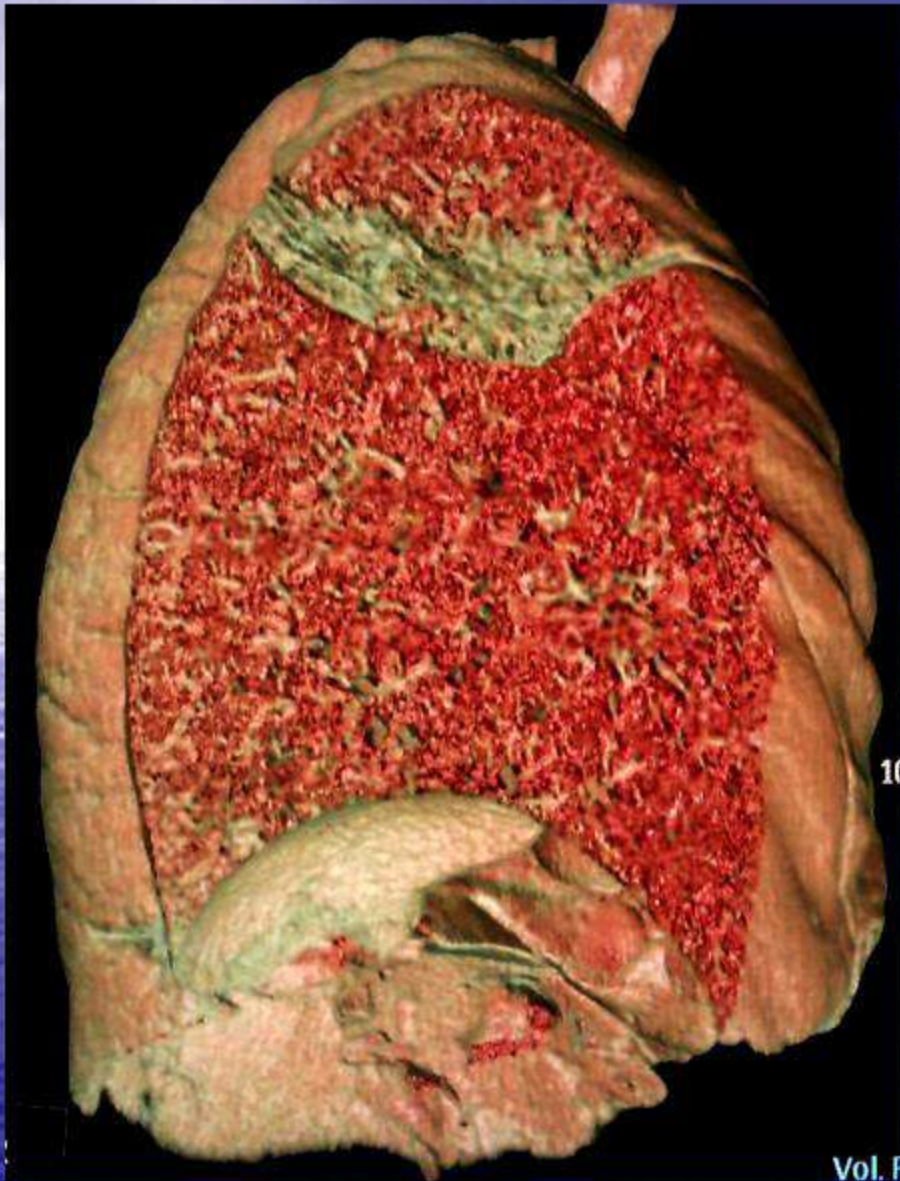

Vo
Op

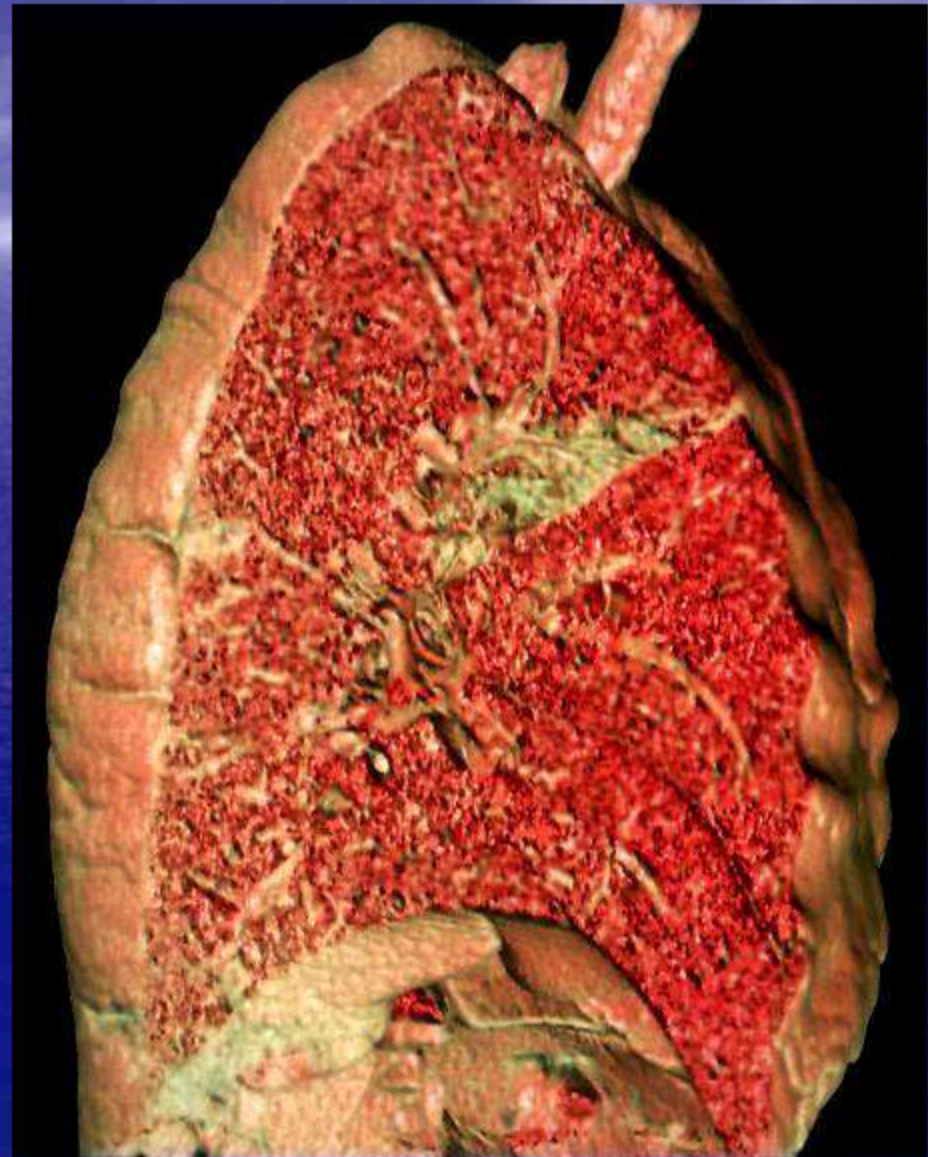
H
P
R

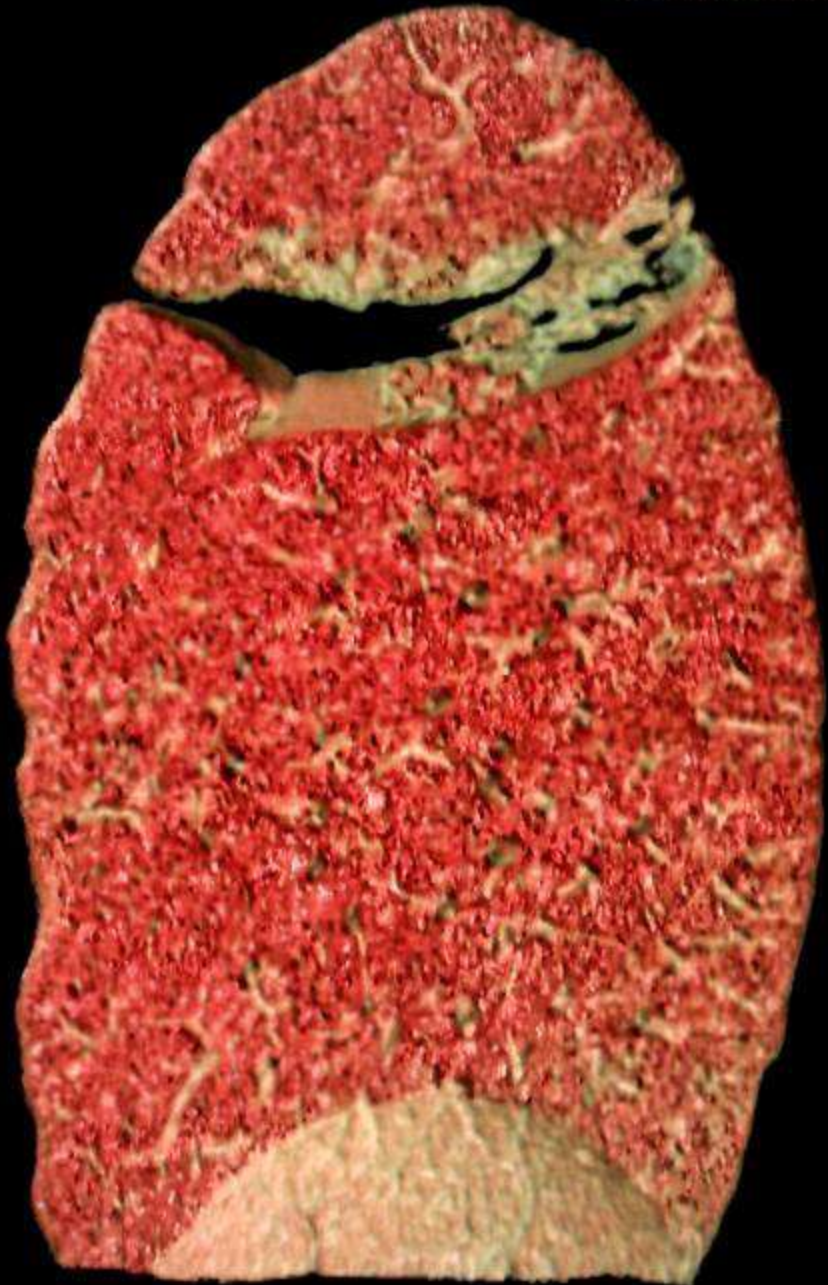10

Vol. I



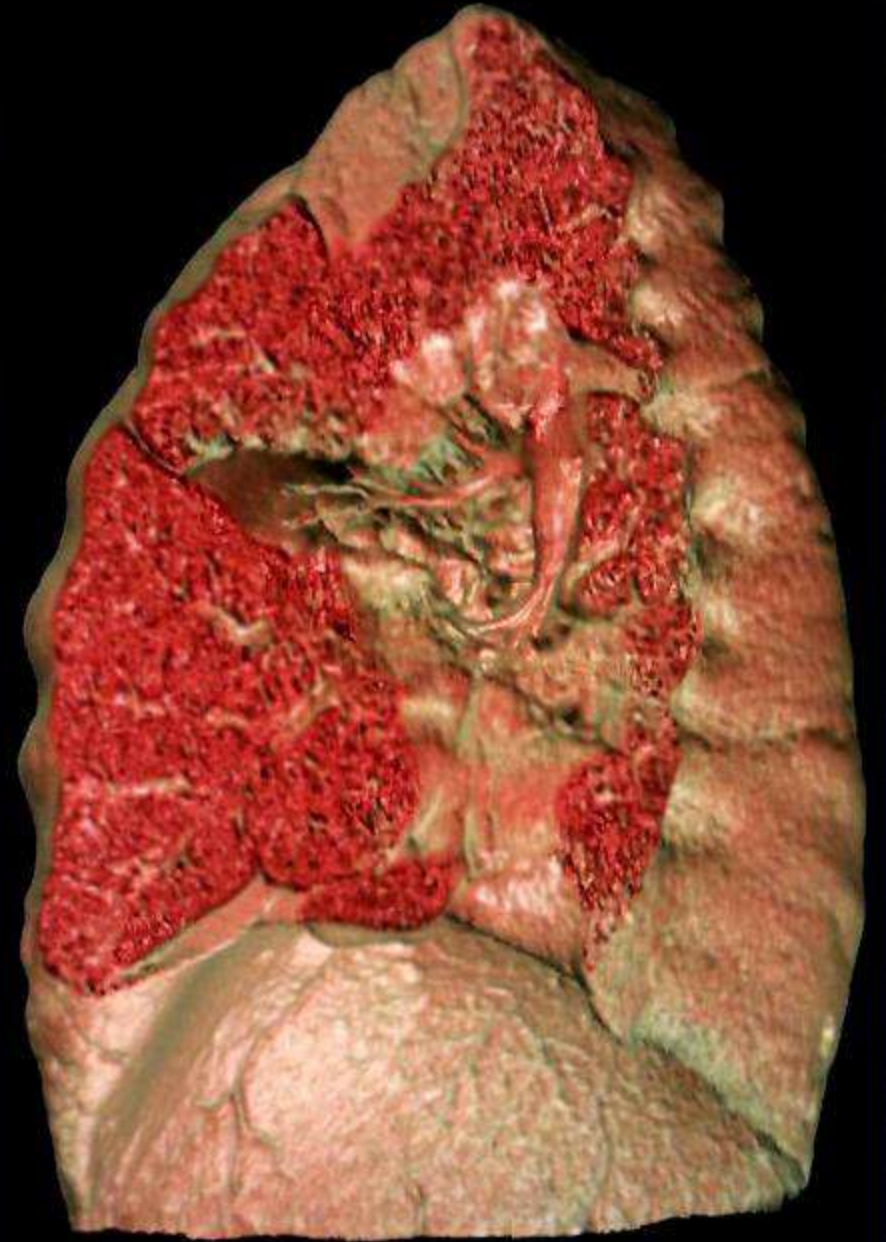
Vol. F





10

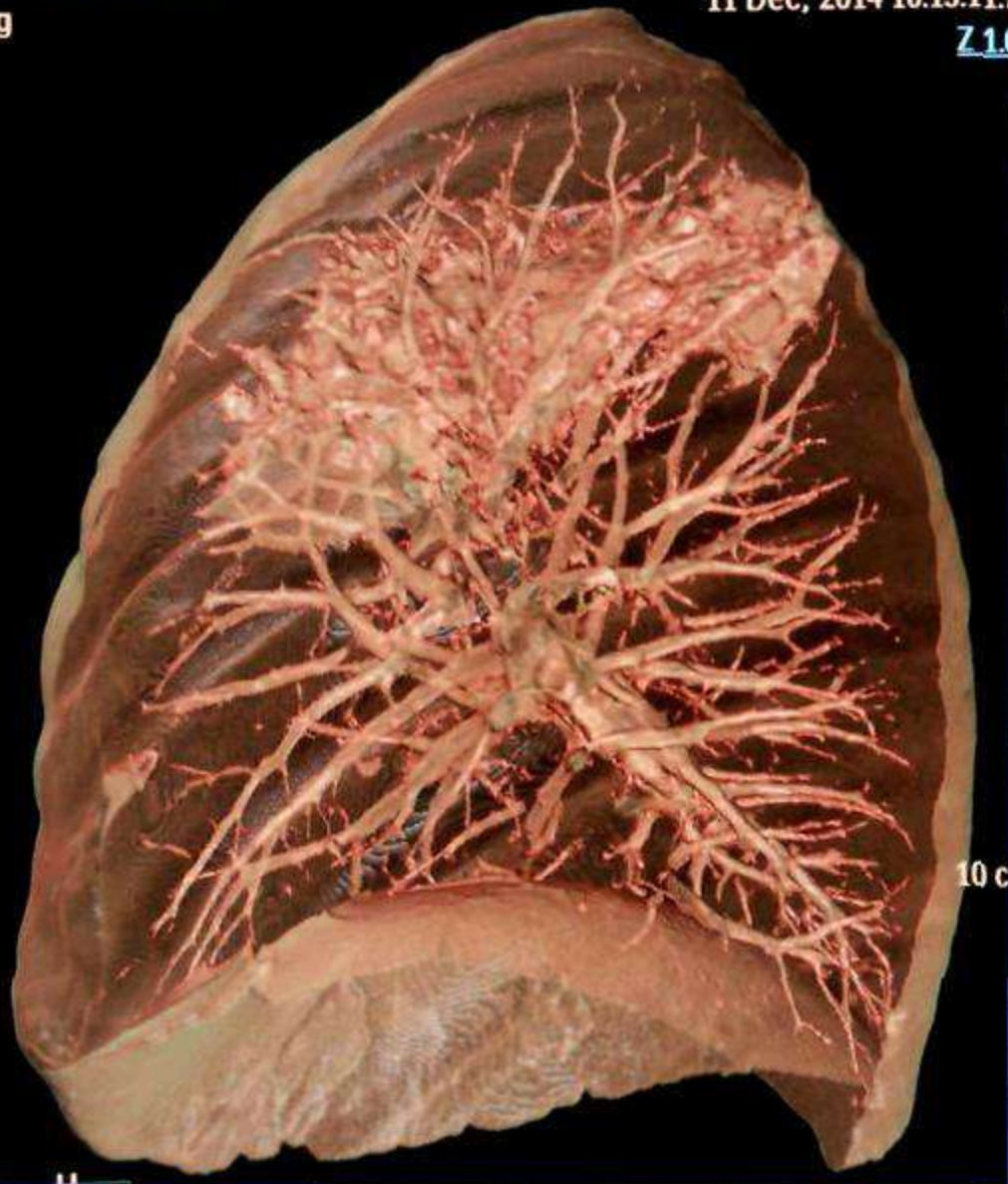
Vol. 1



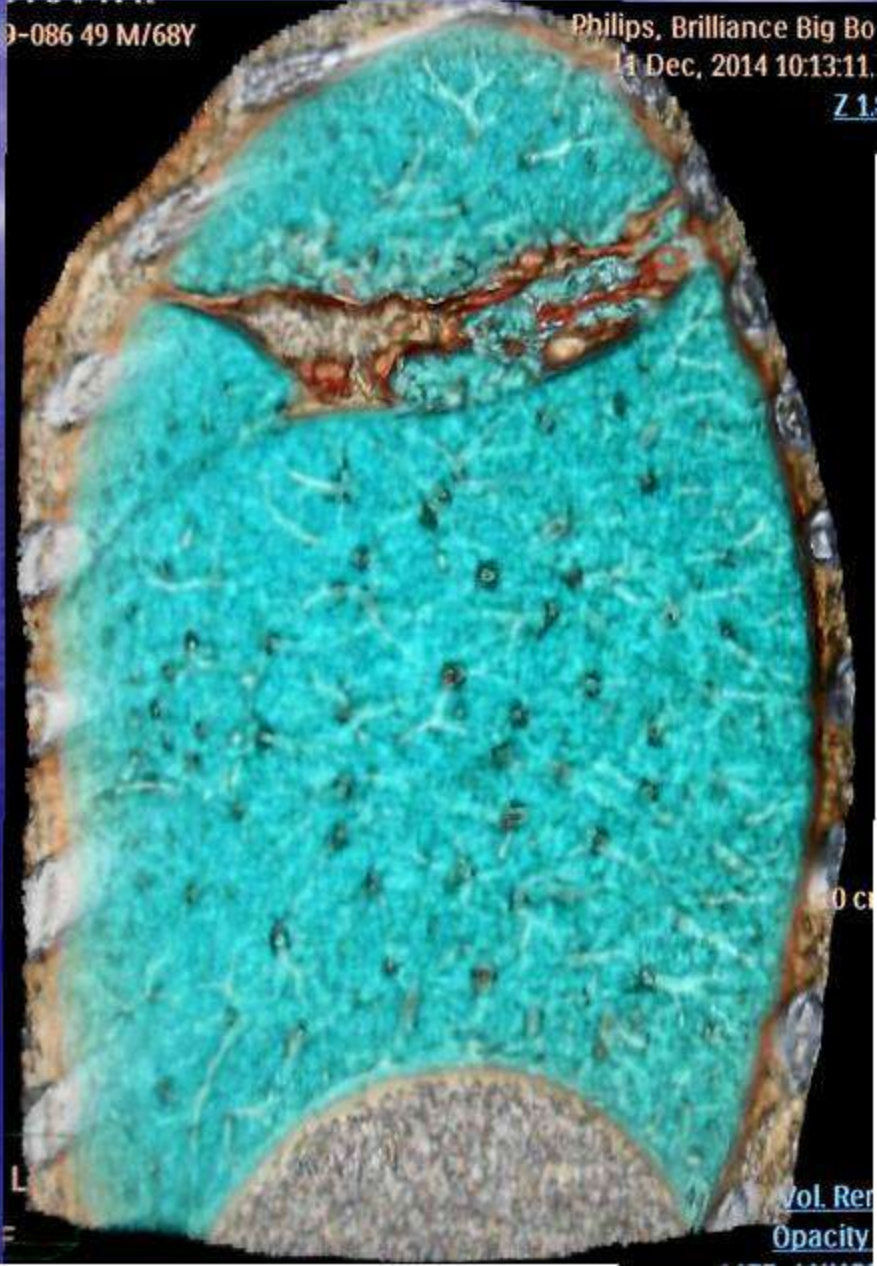9-086 49 M/68Y

11 Dec, 2014 10:13:11.7

Z1.0



10 cm



9-086 49 M/68Y

Philips, Brilliance Big Bo

11 Dec, 2014 10:13:11.7

Z1.0

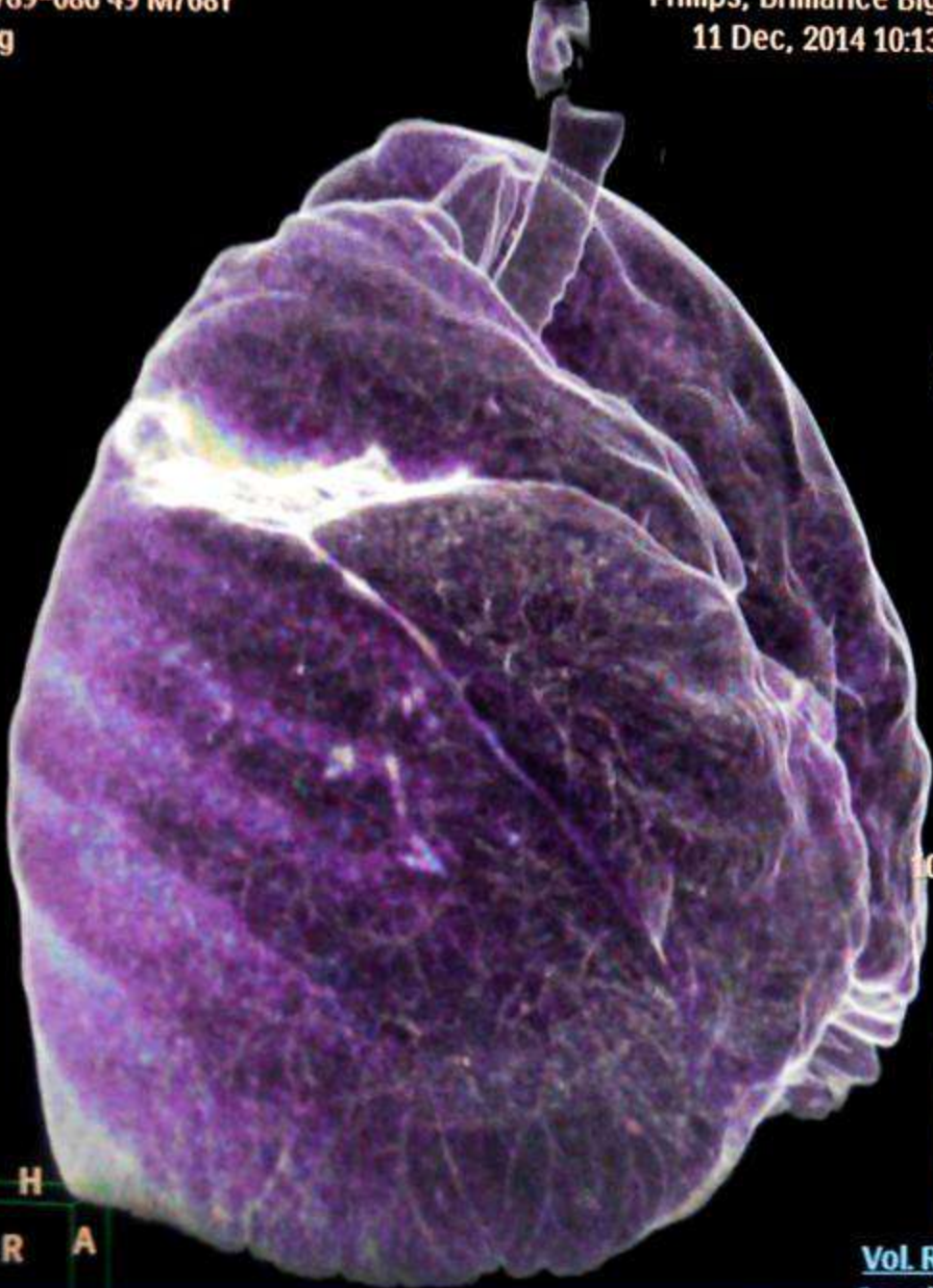10 cm

Vol. Ren

Opacity

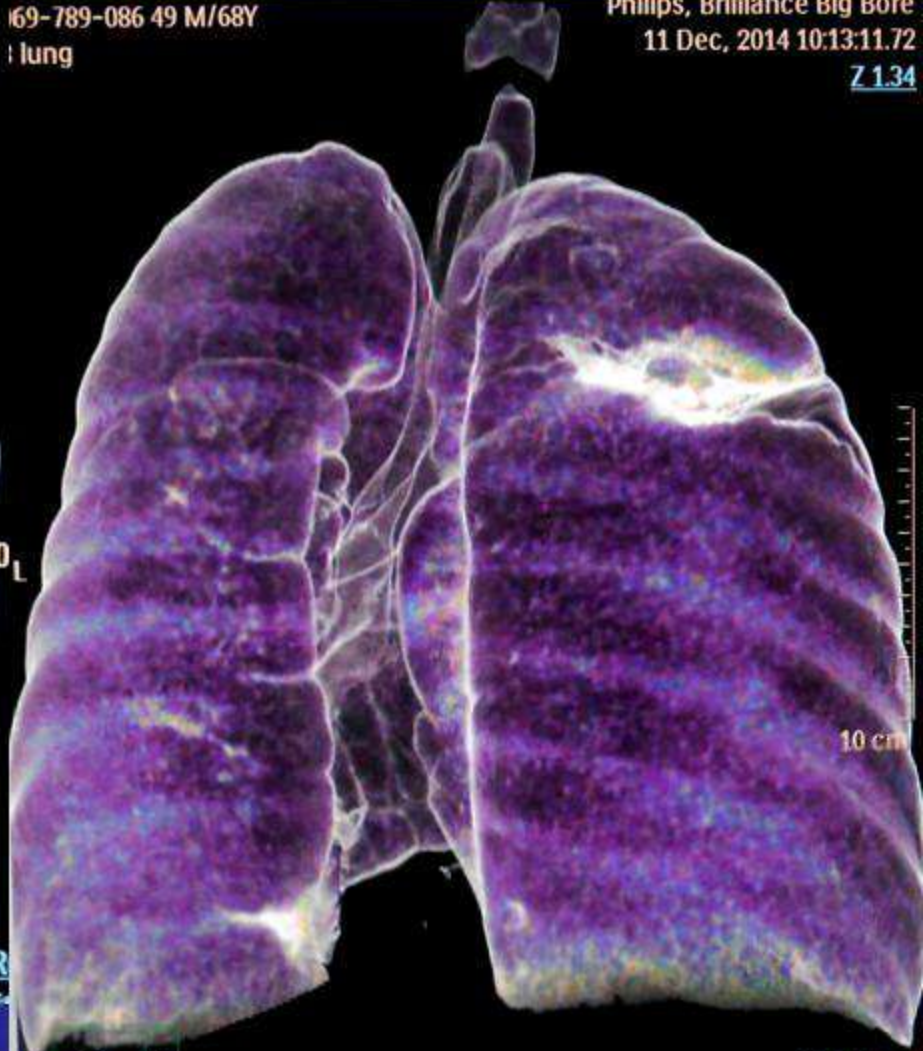
69-789-086 49 M/68Y
lung

Philips, Brilliance Big Bore
11 Dec, 2014 10:13:11
Z



69-789-086 49 M/68Y
lung

Philips, Brilliance Big Bore
11 Dec, 2014 10:13:11.72
Z 134



H
R A

Vol. Rend
Opacit

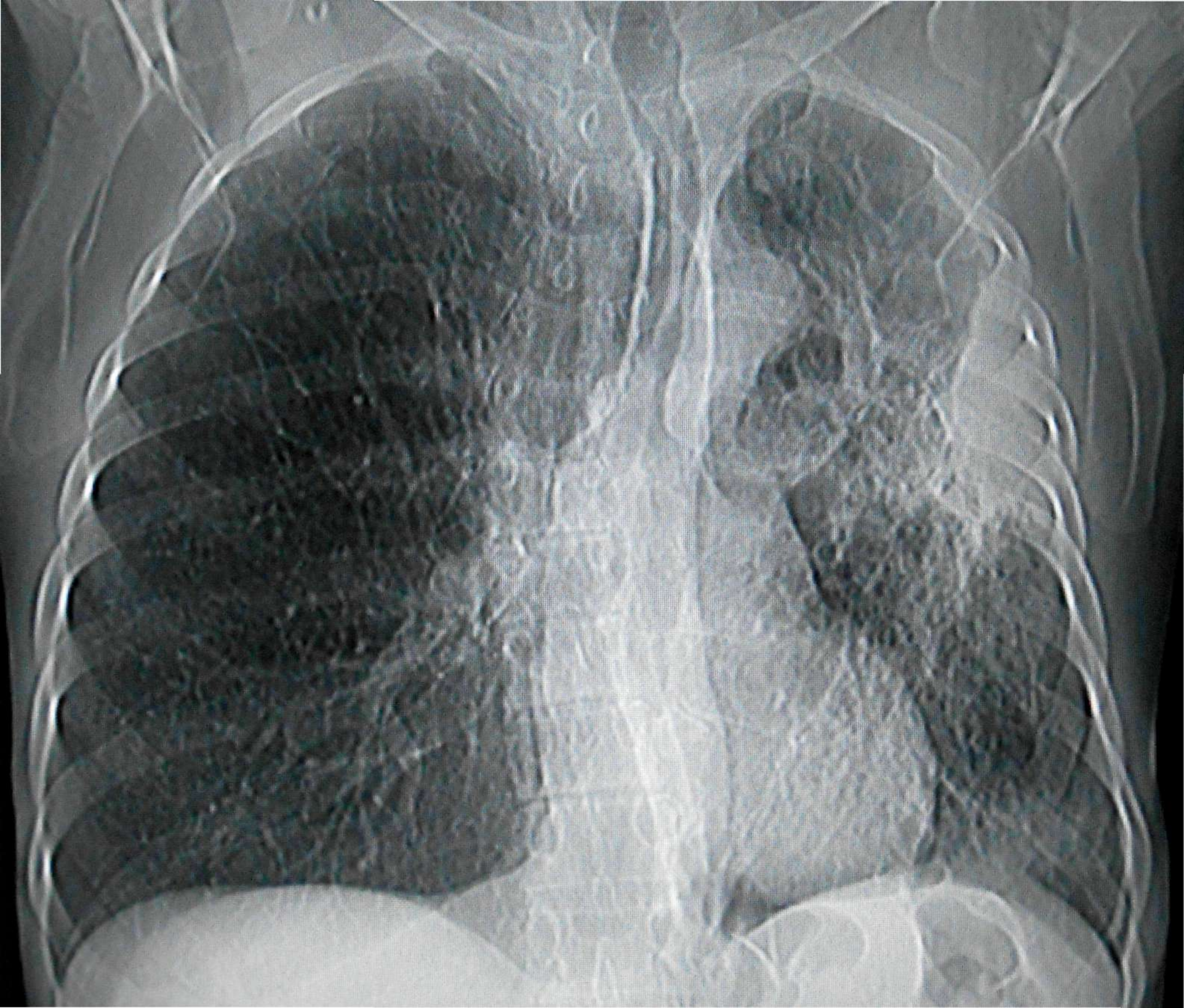
P R

Vol. Rend

Левосторонняя
хроническая полисегментарная
пневмония (пневмосклероз, пневмофиброз,
карнификация, цирроз).

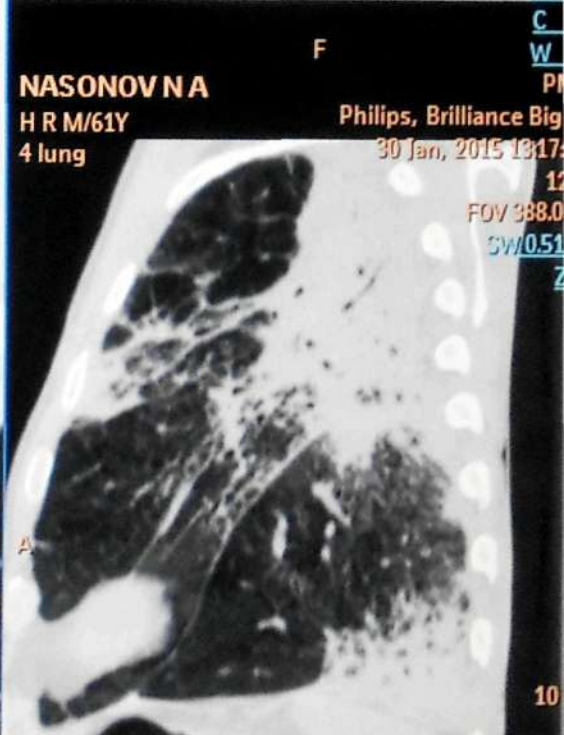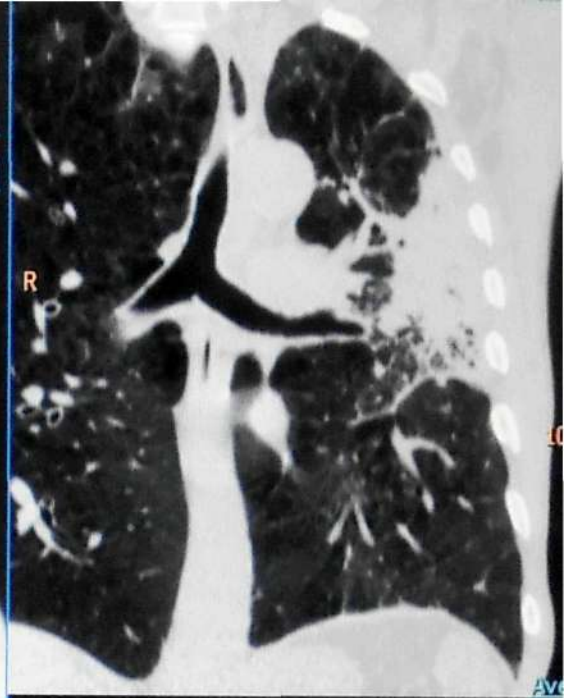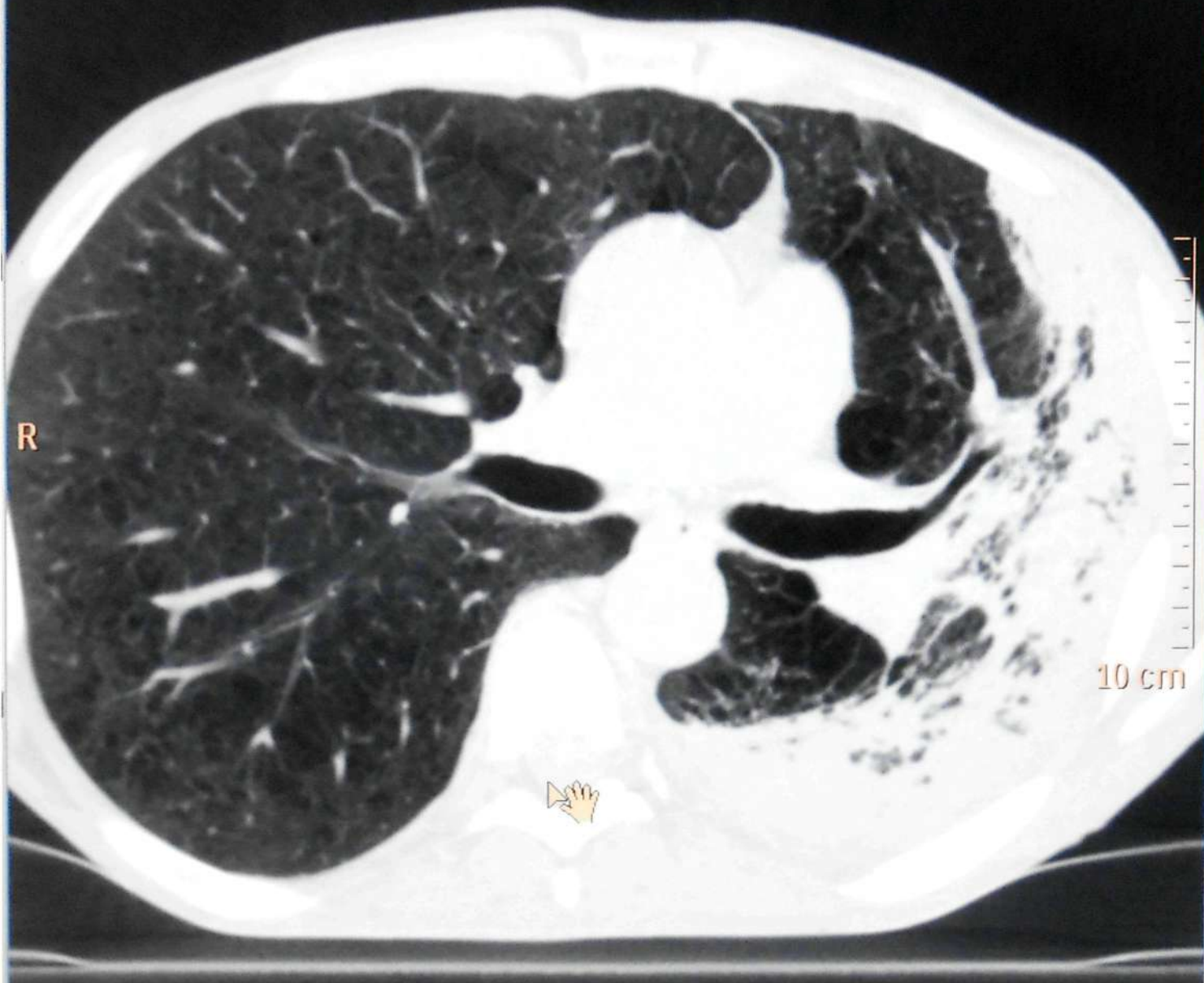
МСКТ. Наблюдение из практики.

Бодров Ю.Д. *канд. мед. наук.*



517.5 mm

120 KV
FOV 388.0 mm
SW 2.00 mm
Z 1.33



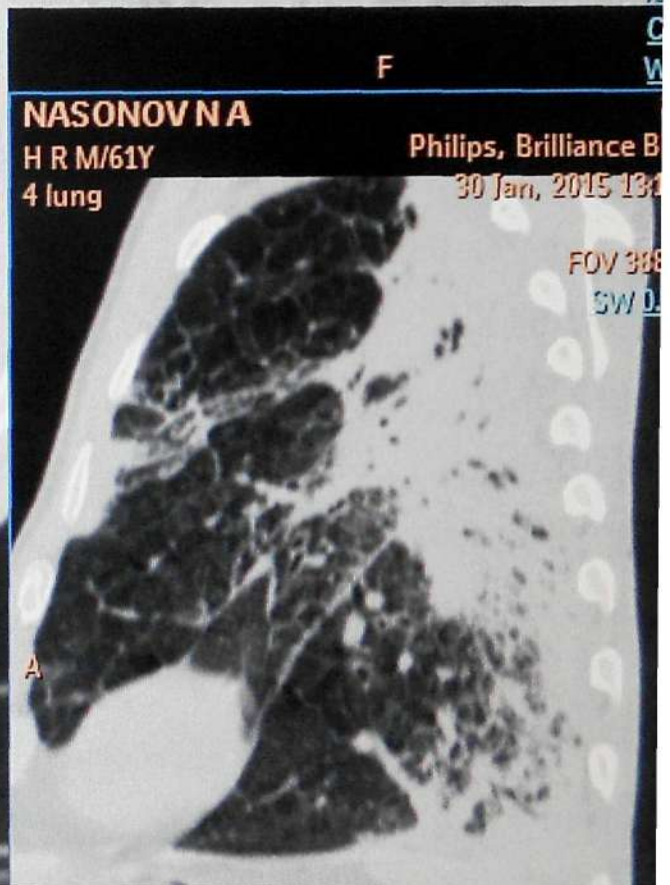
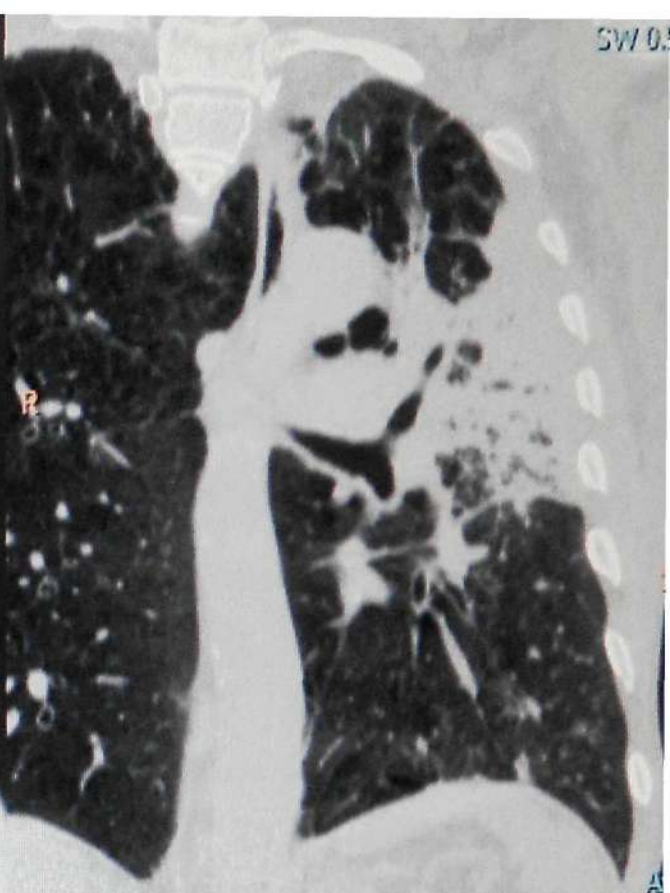
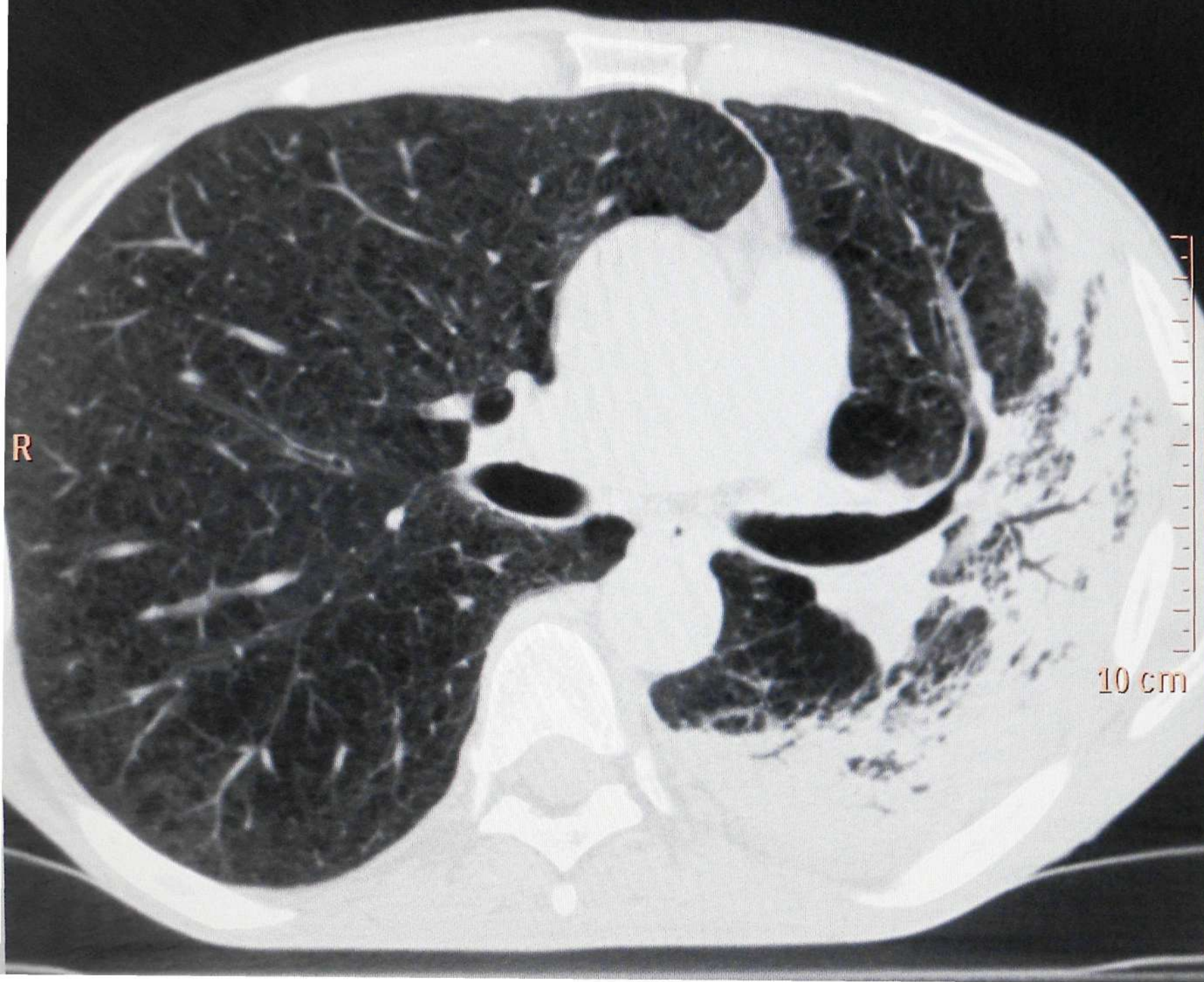
NASONOV NA
H R M/61Y
4 lung

Philips, Brilliance Big
30 Jan, 2015 13:17

FOV 388.0
SW 0.51
Z

4-155* lung
-515.9 mm

120 kV
FOV 388.0 mm
SW 2.00 mm
Z 1.33



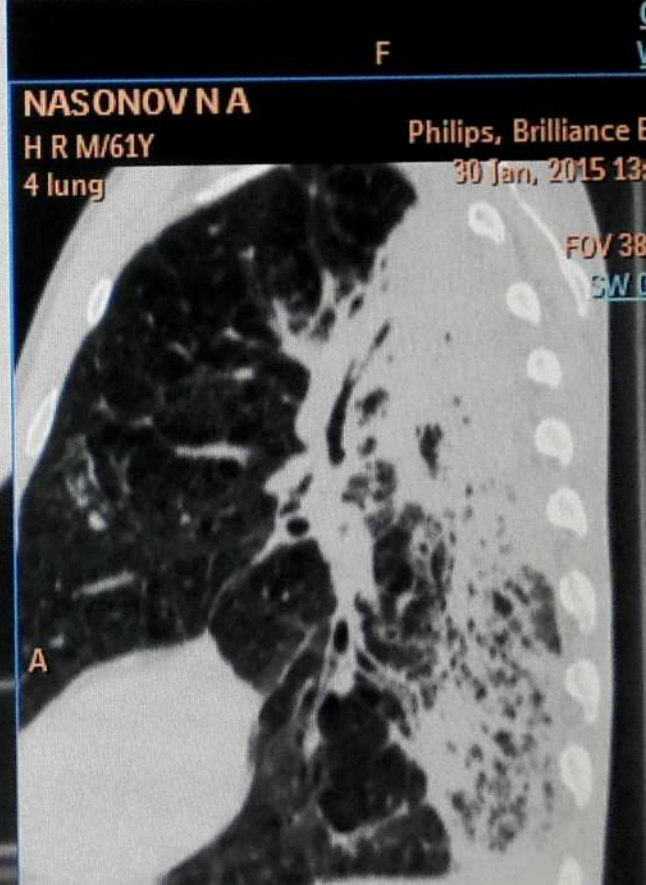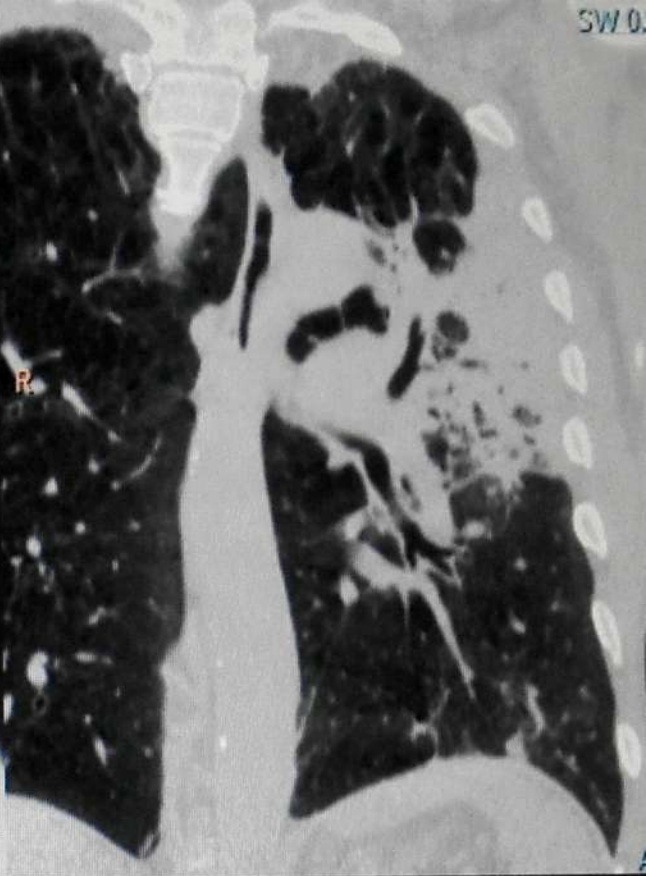
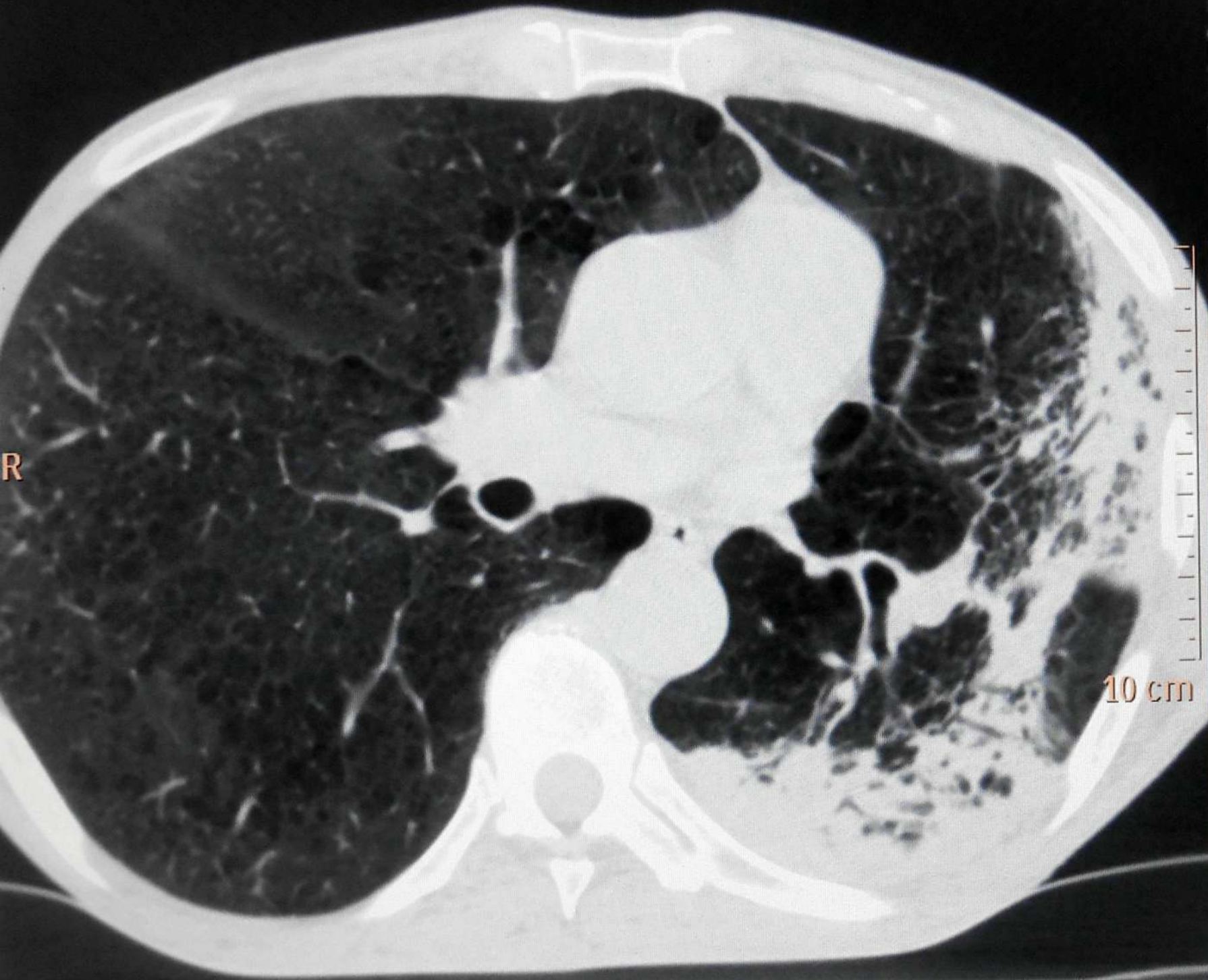
NASONOV NA
H R M/61Y
4 lung

Philips, Brilliance B
30 Jan, 2015 13:0

FOV 388
SW 2.00

100 Rang
-502.9 mm

120 kV
FOV 388.0 mm
SW 2.00 mm
Z 1.33



NASONOV N A
H R M/61Y
4 lung
Philips, Brilliance E
30 Jan, 2015 13:30

FOV 388.0 mm
SW 2.00 mm

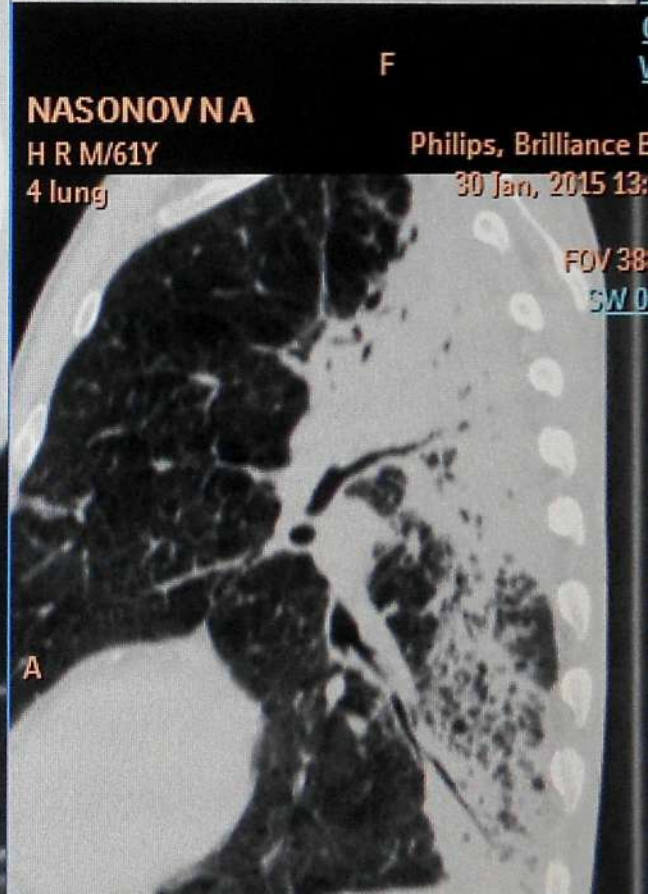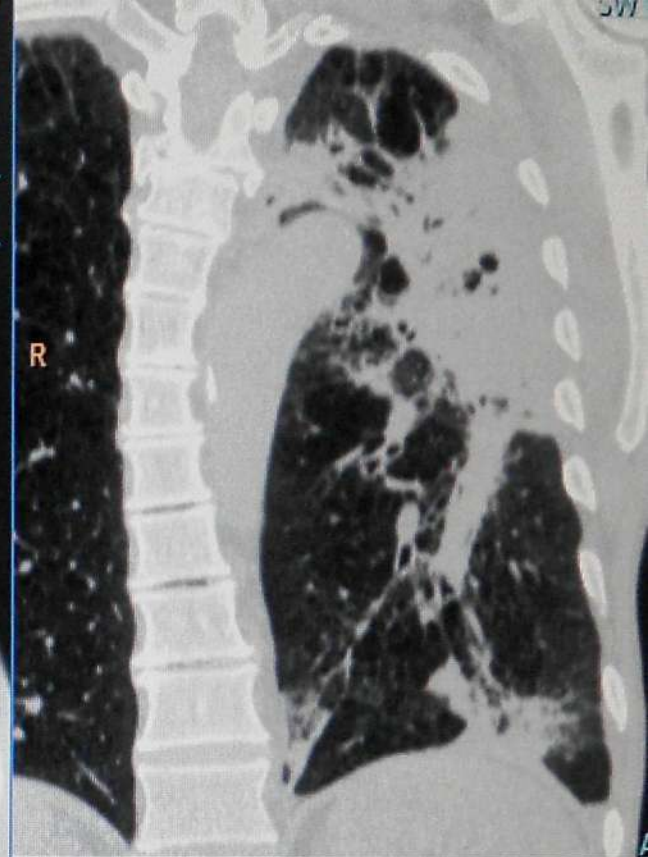
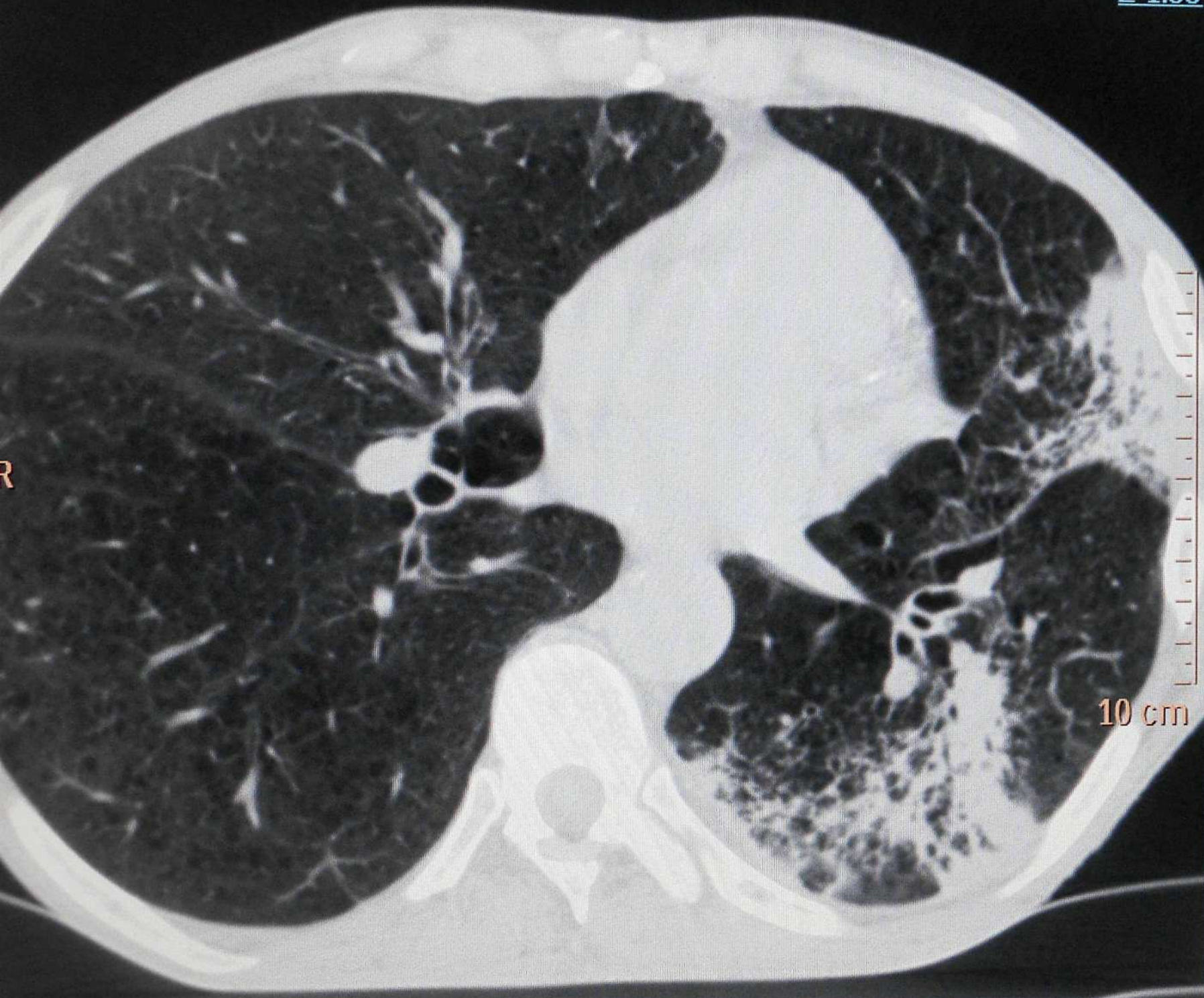
77.5 mm

120 kV

FOV 388.0 mm

SW 2.00 mm

Z 1.33



NASONOVNA
H R M/61Y
4 lung

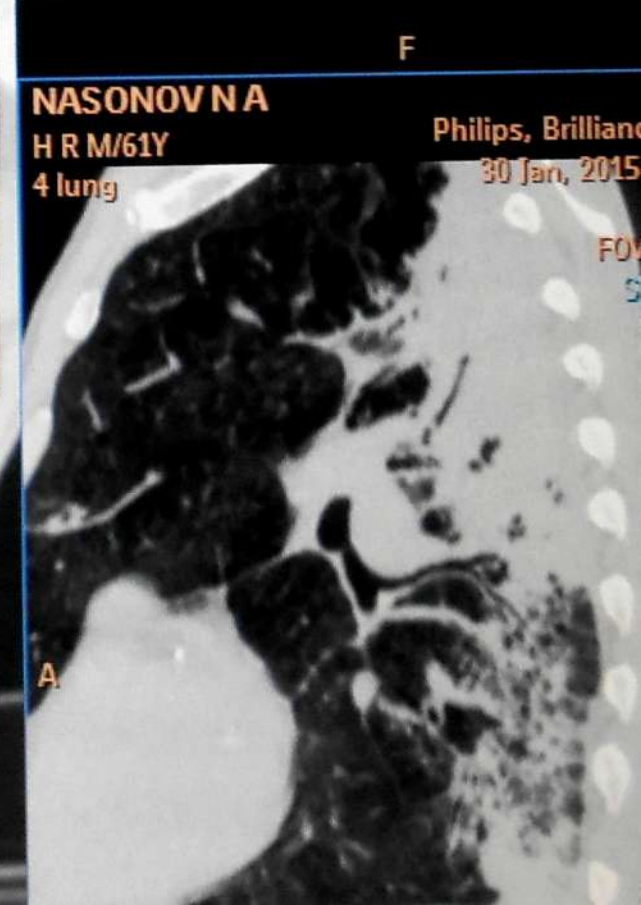
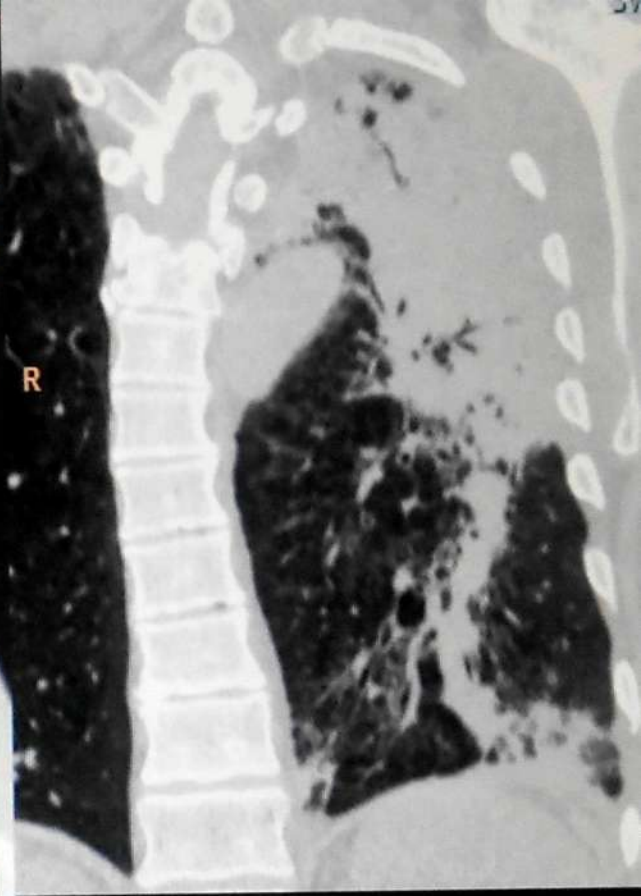
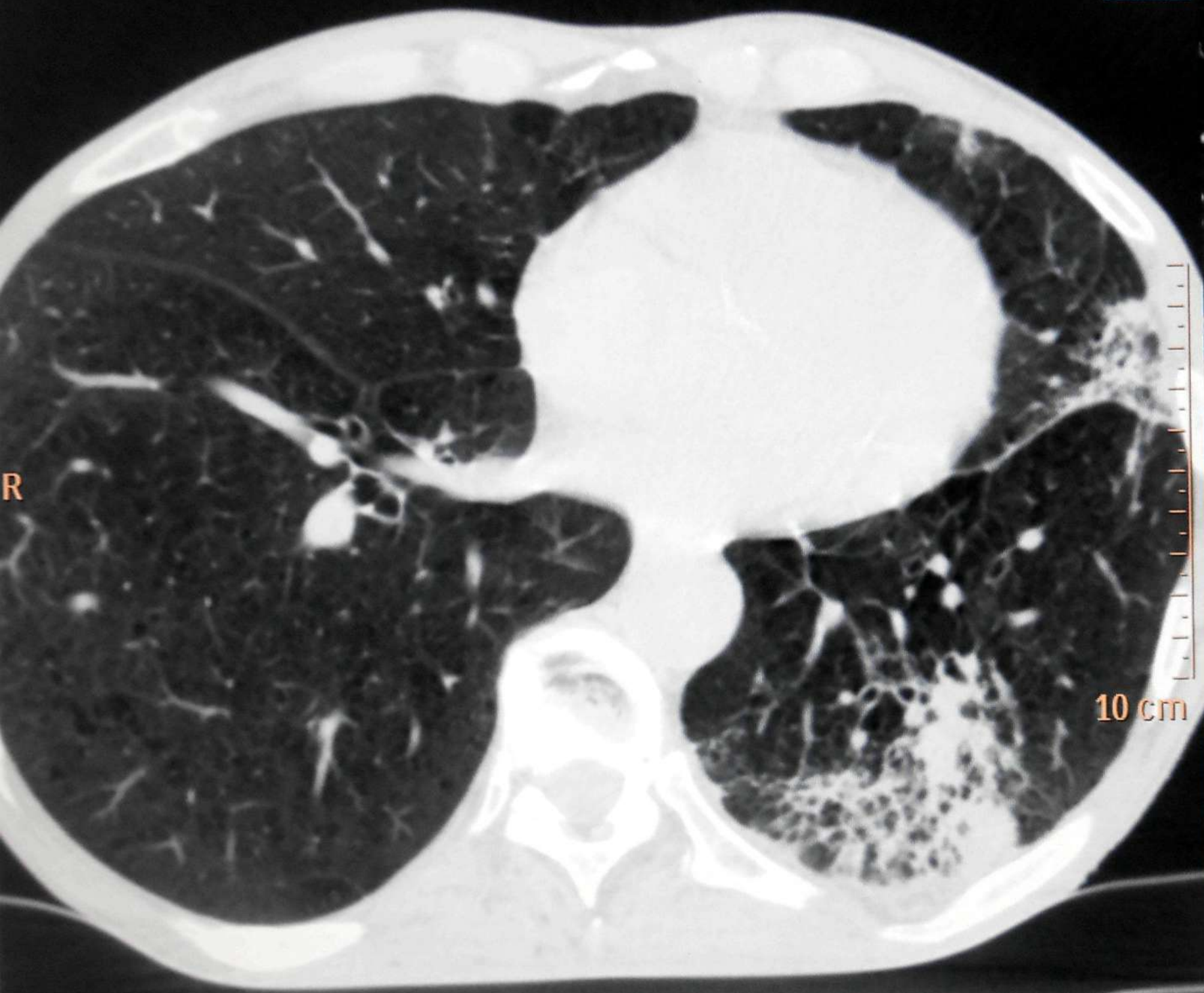
Philips, Brilliance E
30 Jan, 2015 13:

FOV 388.0 mm
SW 2.00 mm

10 cm

213 lung
-457.9 mm

120 kV
FOV 388.0 mm
SW 2.00 mm
Z 1.33



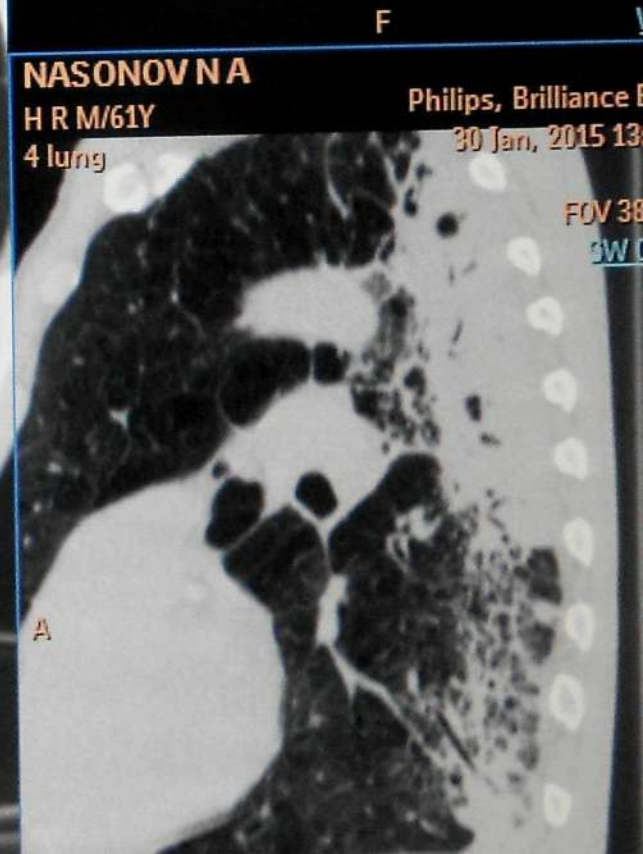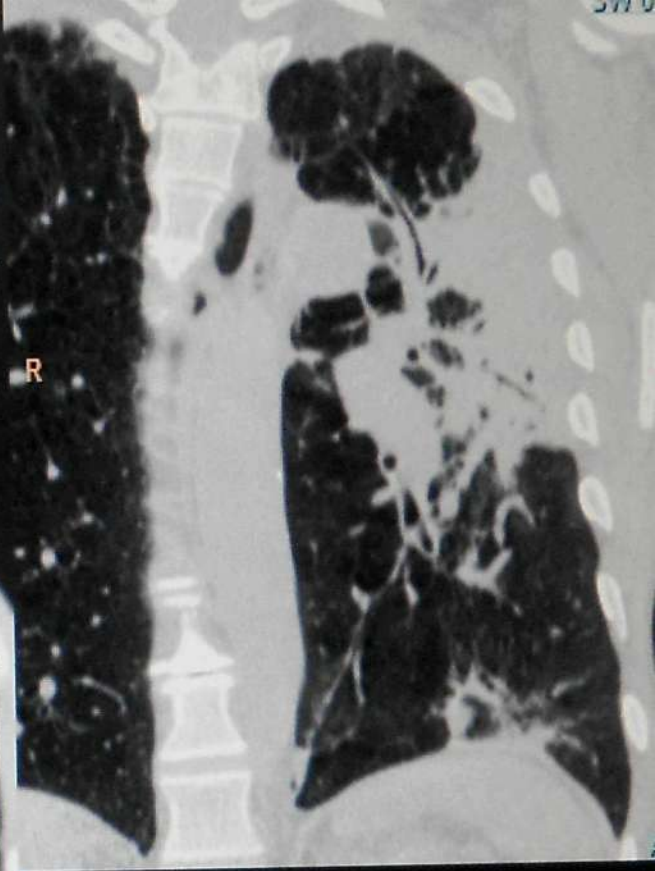
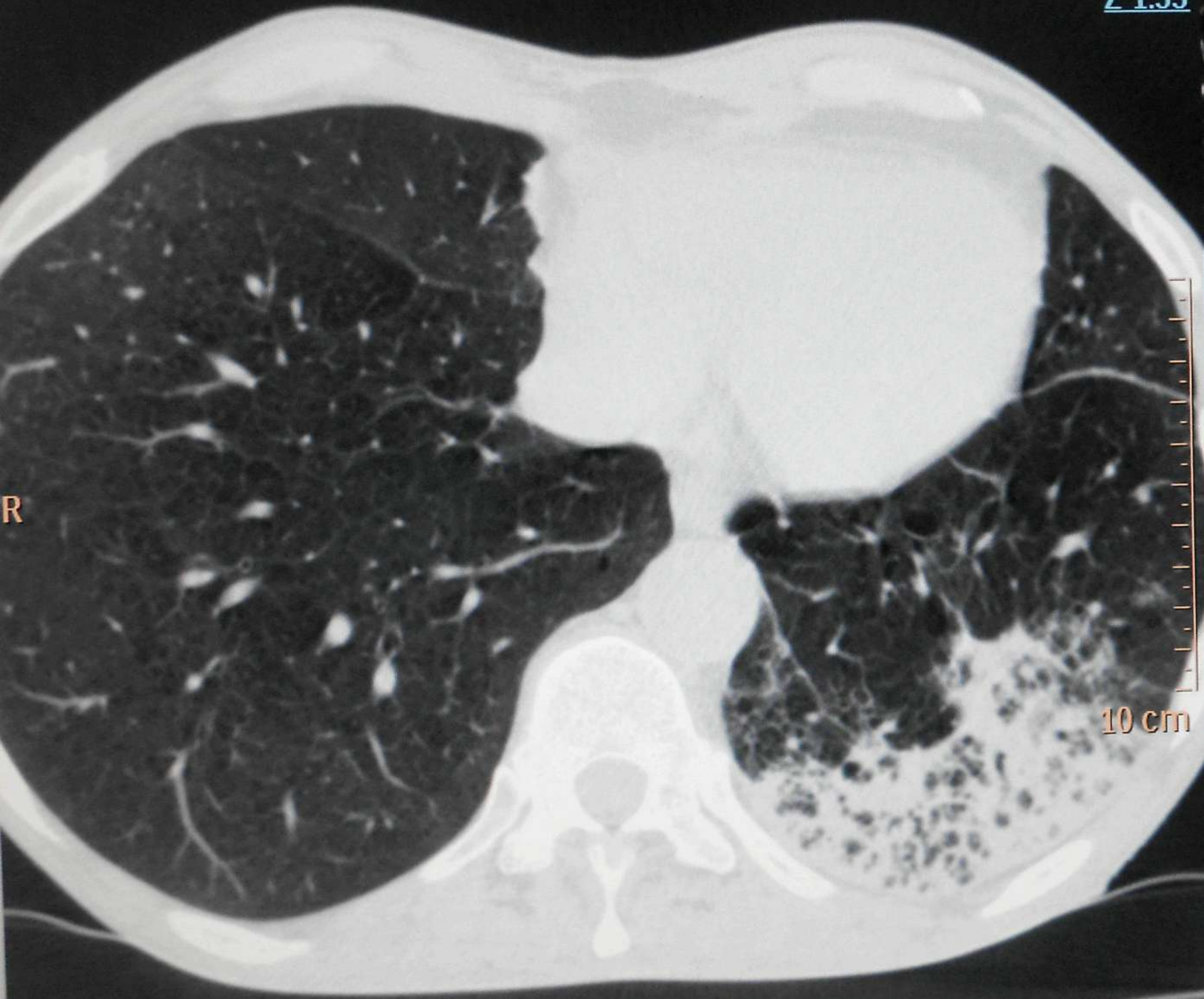
NASONOV NA
H R M/61Y
4 lung

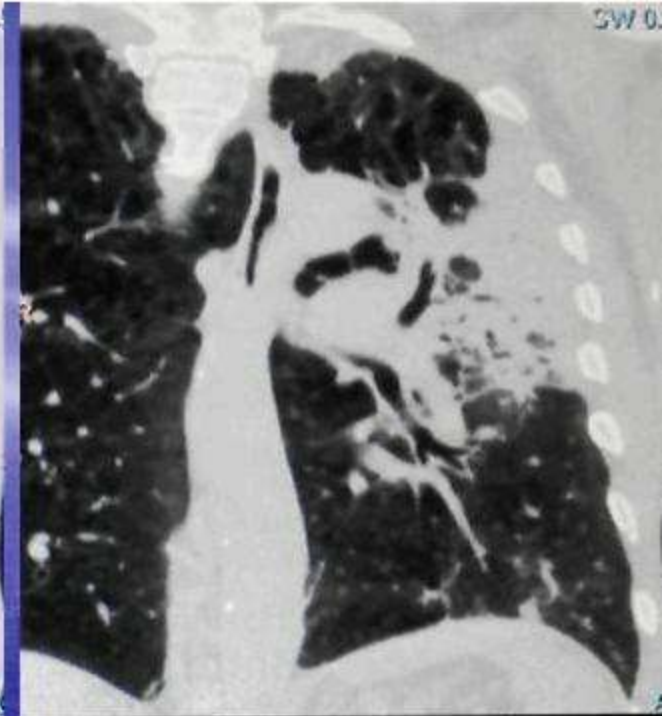
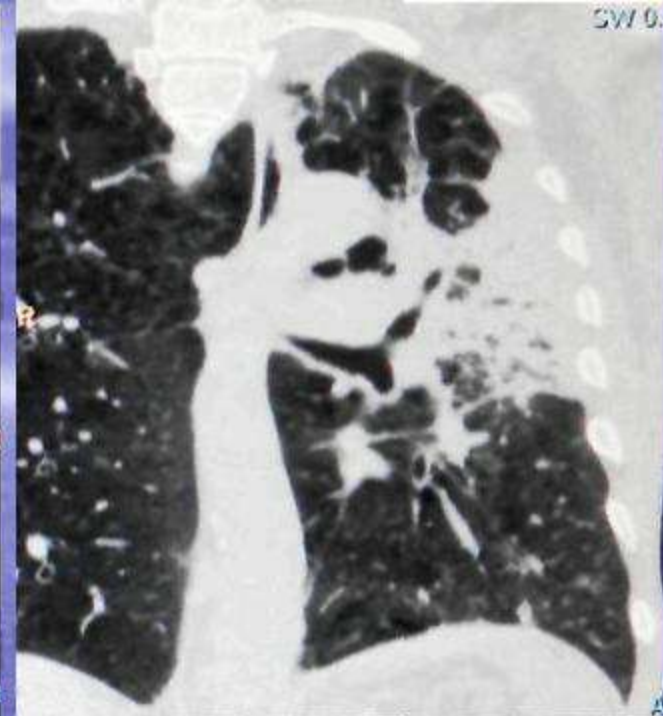
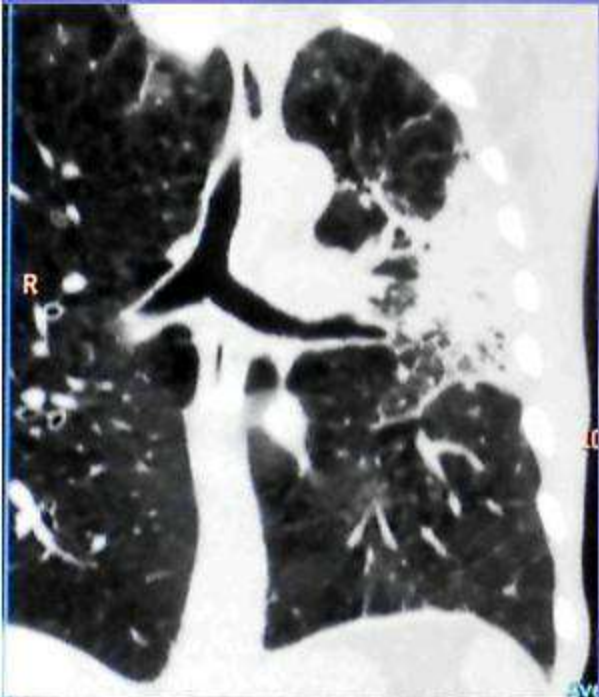Philips, Brilliance
30 Jan, 2015

FOV
388.0 mm

421.9 mm

120 kV
FOV 388.0 mm
SW 2.00 mm
Z 1.33

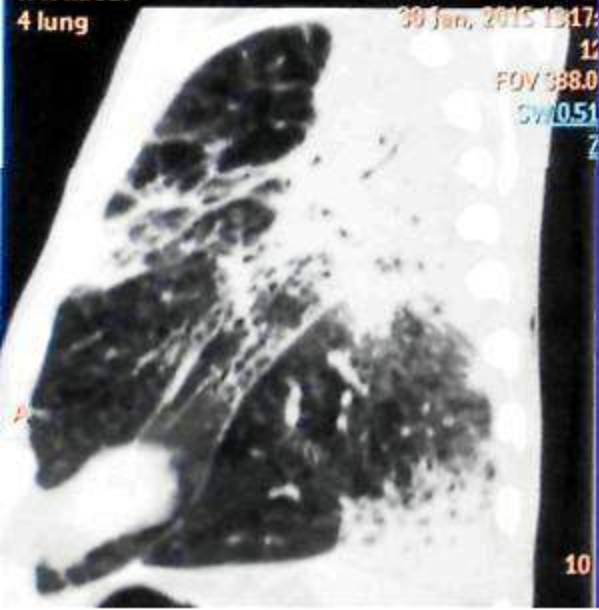




NASONOV N A
H R M/61Y
4 lung

Philips, Brilliance Big
30 Jan, 2015 19:17:12

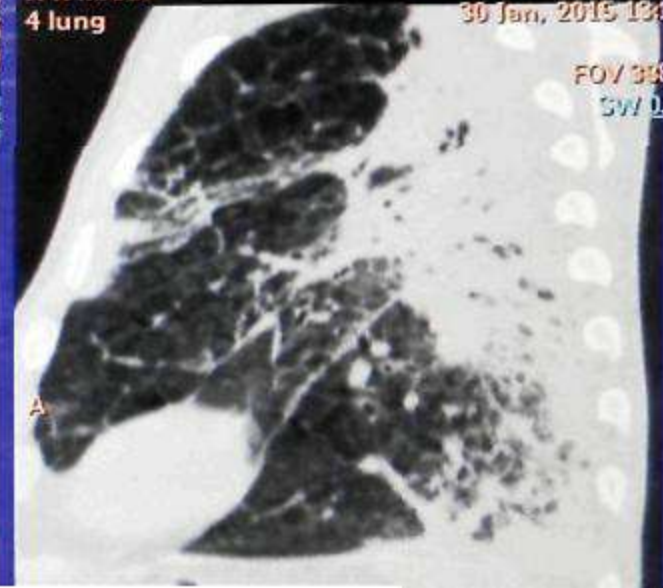
FOV 388.0
SW 0.51



NASONOV N A
H R M/61Y
4 lung

Philips, Brilliance B
30 Jan, 2015 19:17:12

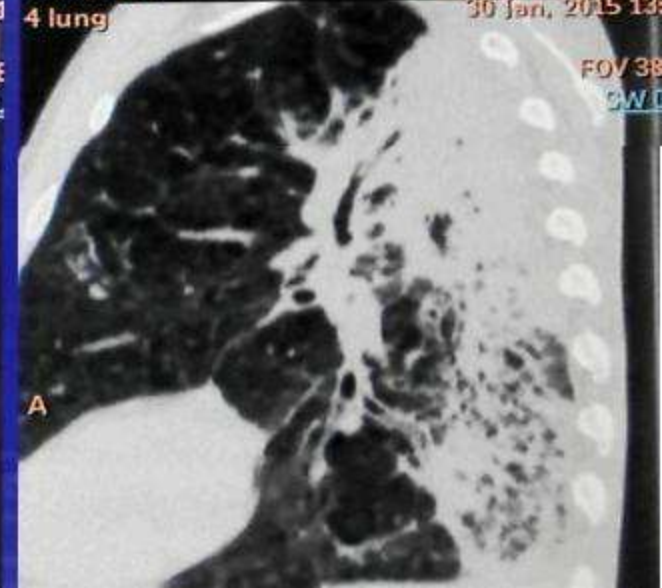
FOV 388.0
SW 0.51

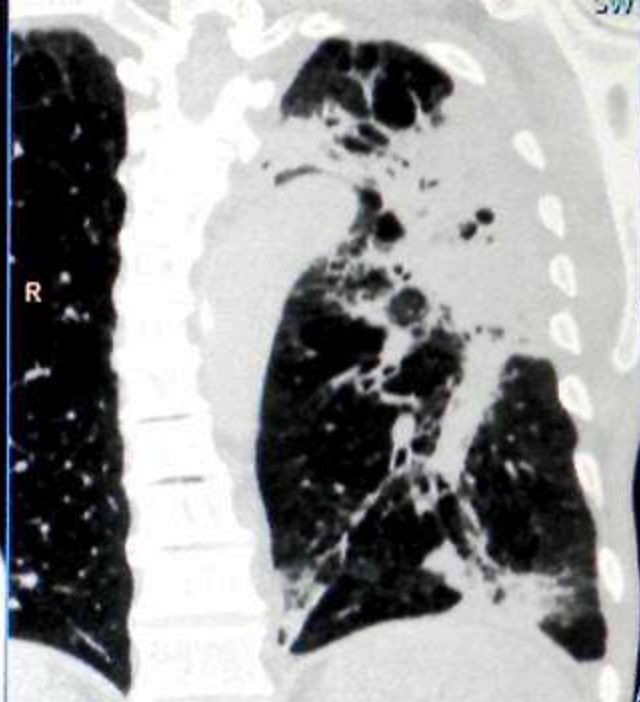


NASONOV N A
H R M/61Y
4 lung

Philips, Brilliance B
30 Jan, 2015 19:17:12

FOV 388.0
SW 0.51





F

NASONOV N A

H R M/61Y

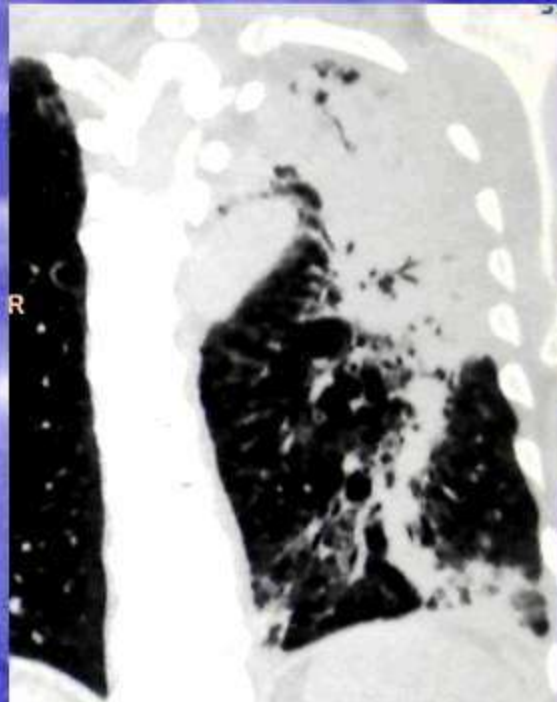
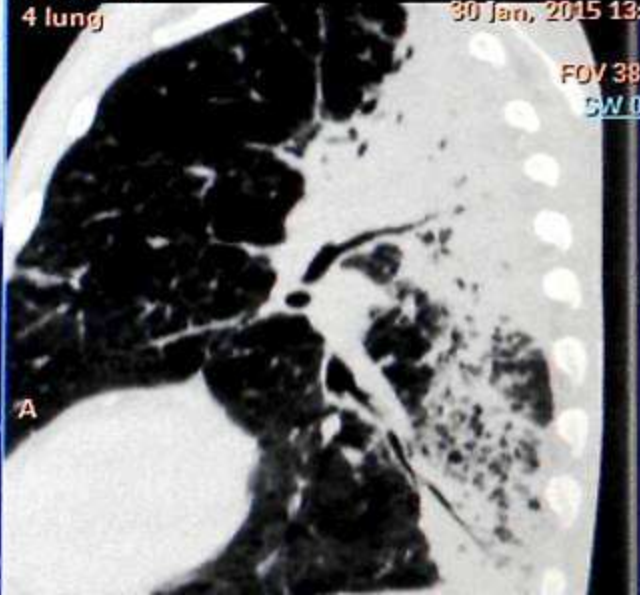4 lung

Philips, Brilliance E

30 Jan, 2015 13:

FOV 38

SW 0



F

NASONOV N A

H R M/61Y

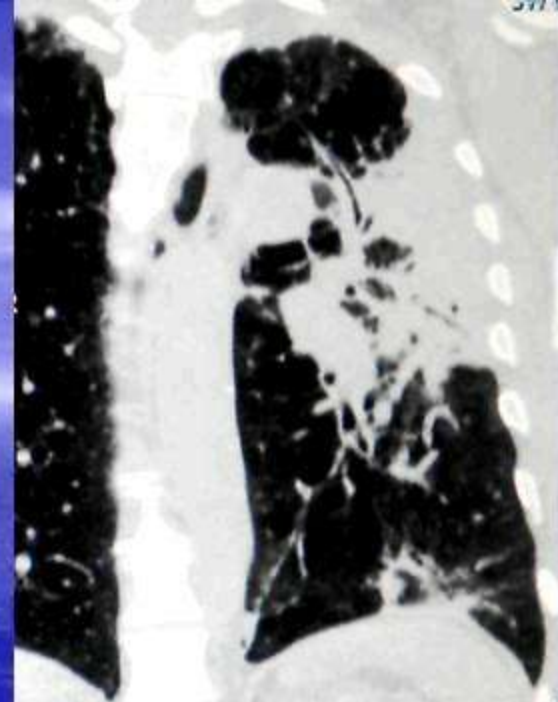
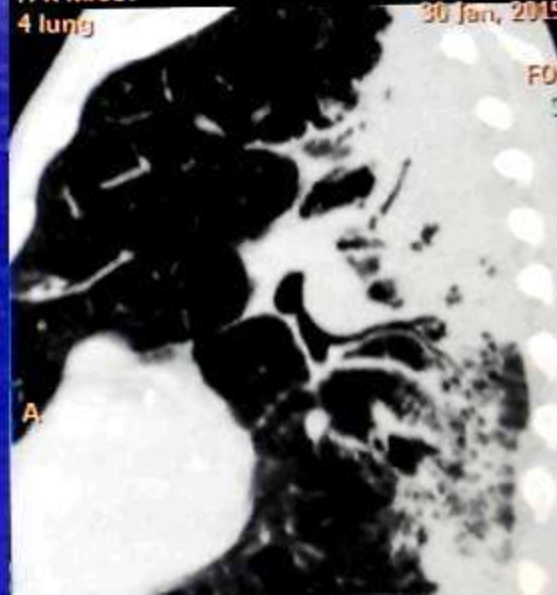
4 lung

Philips, Brilliance E

30 Jan, 2015

FOV 38

SW 0



F

NASONOV N A

H R M/61Y

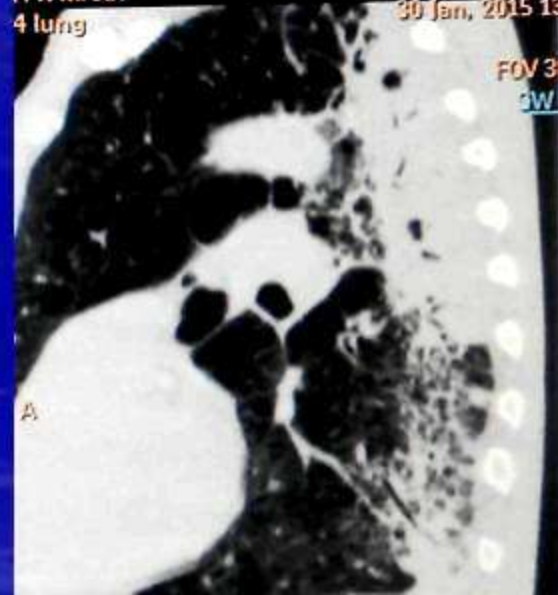
4 lung

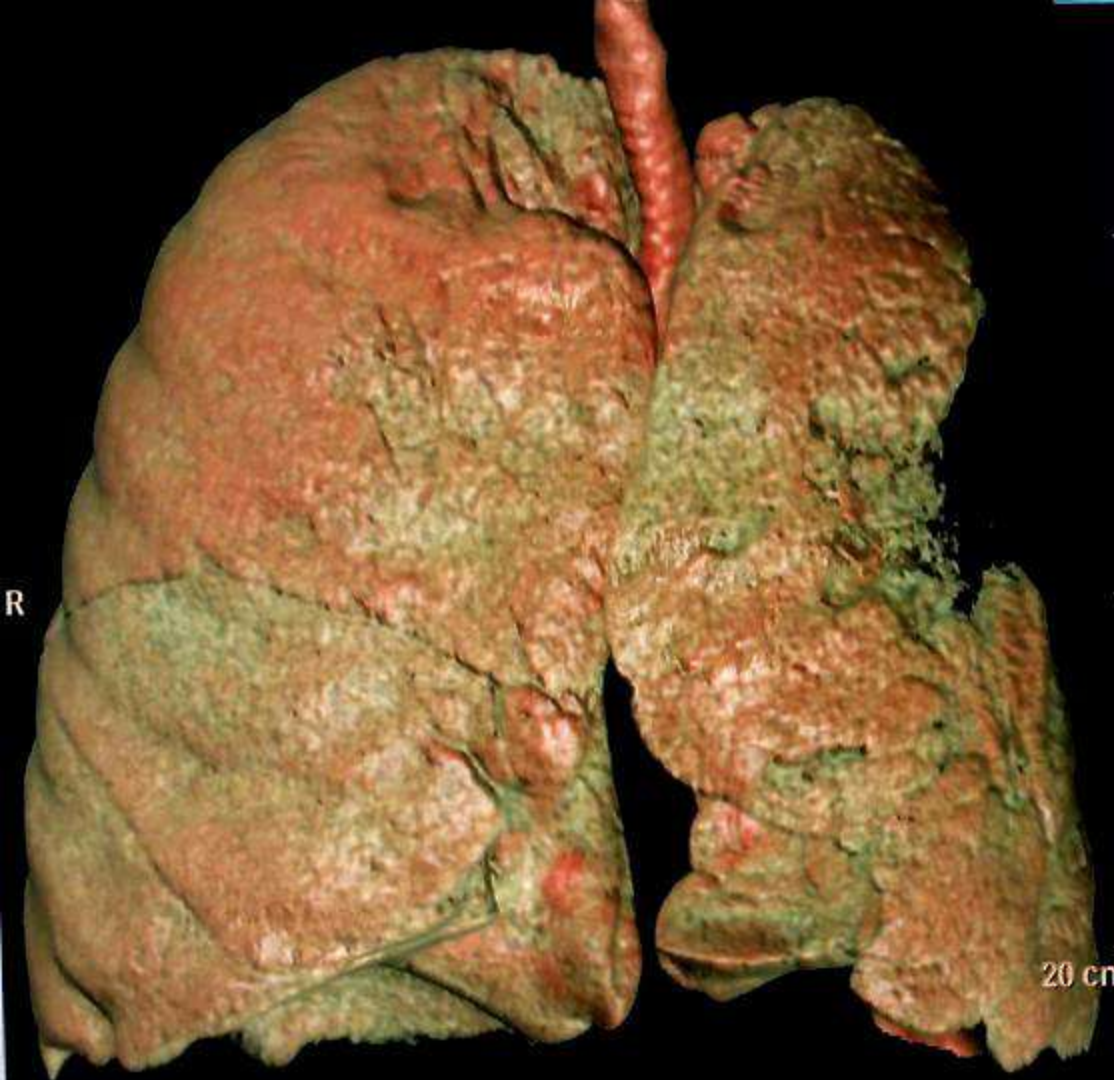
Philips, Brilliance E

30 Jan, 2015 13:

FOV 38

SW 0



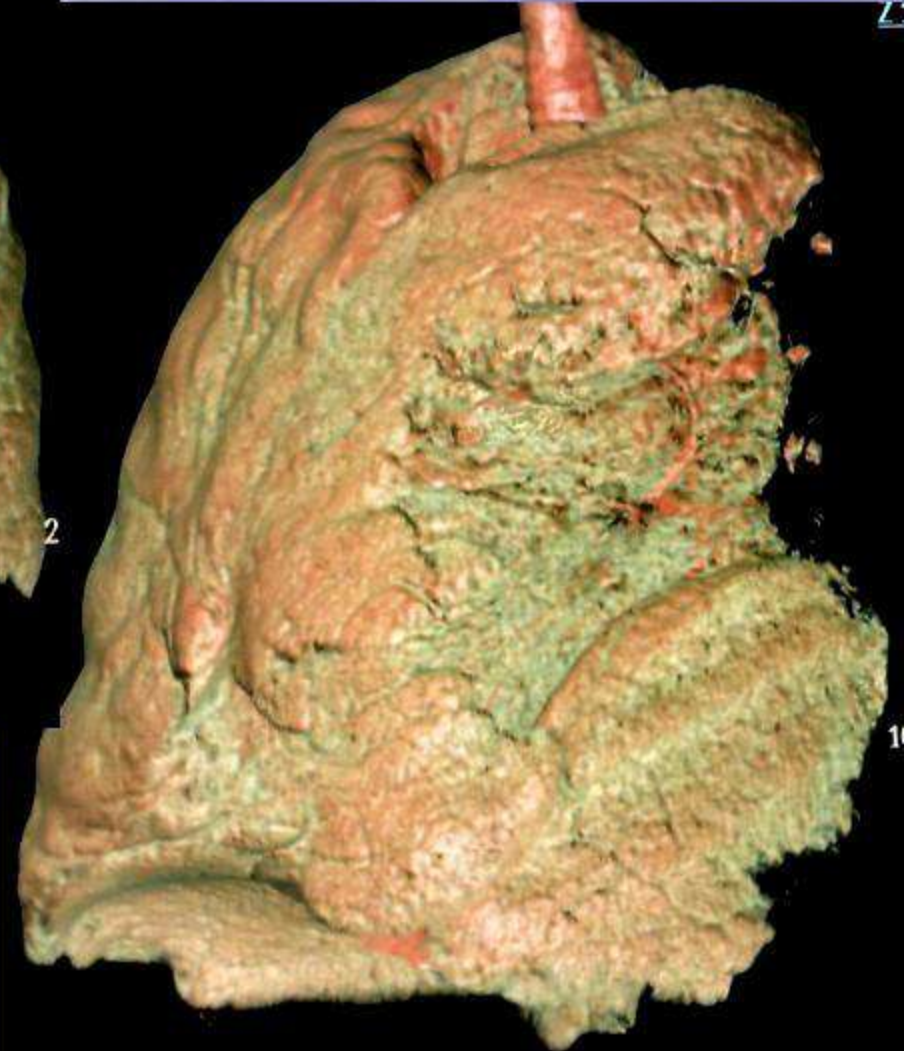
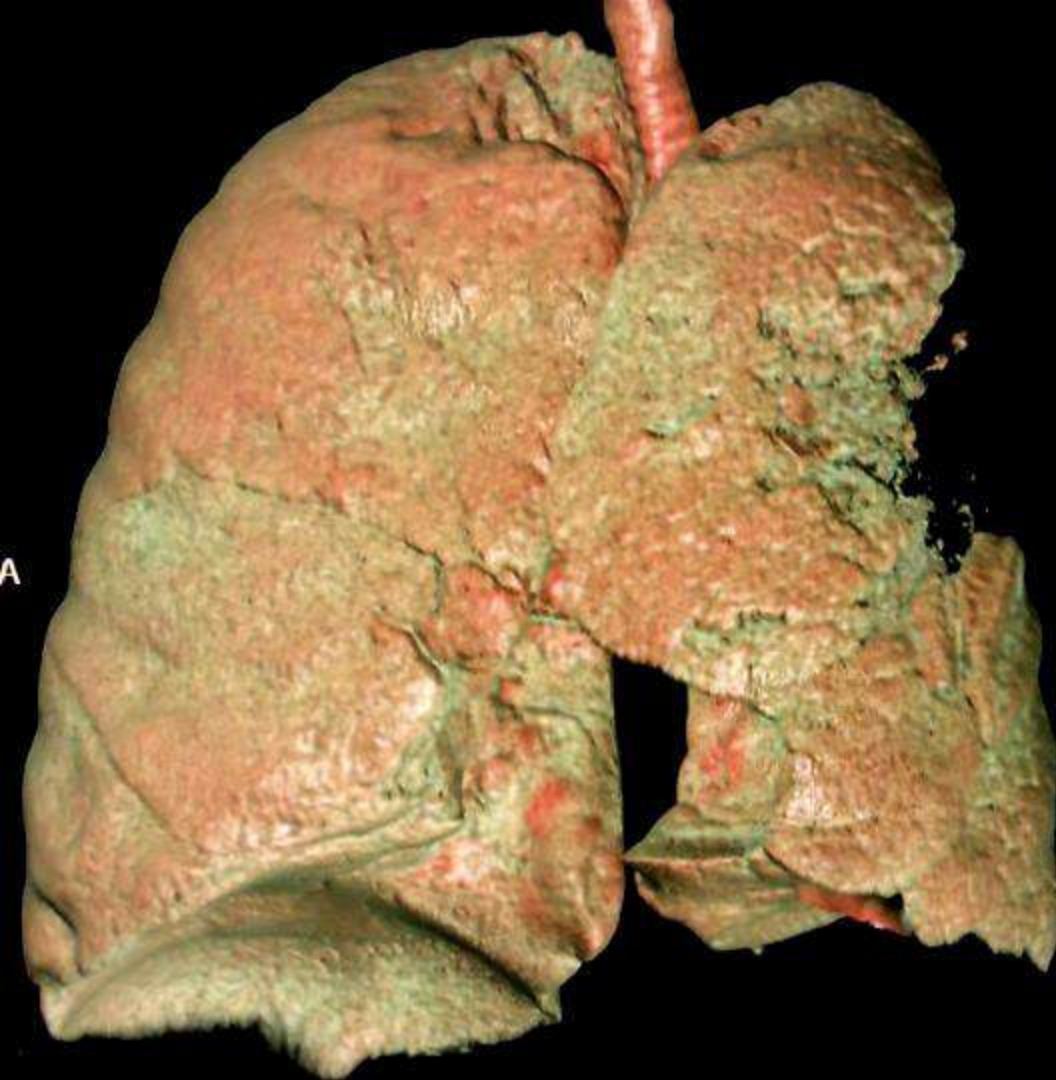

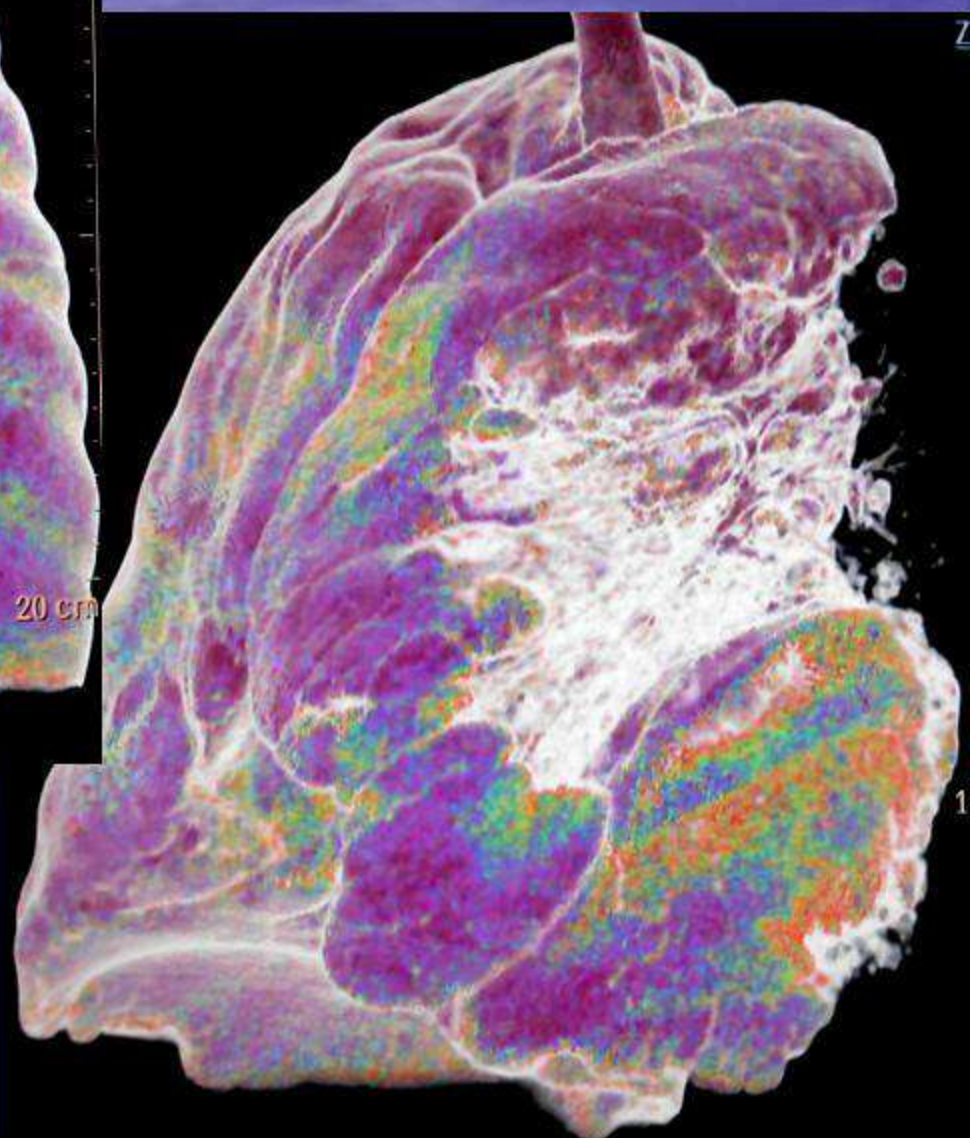
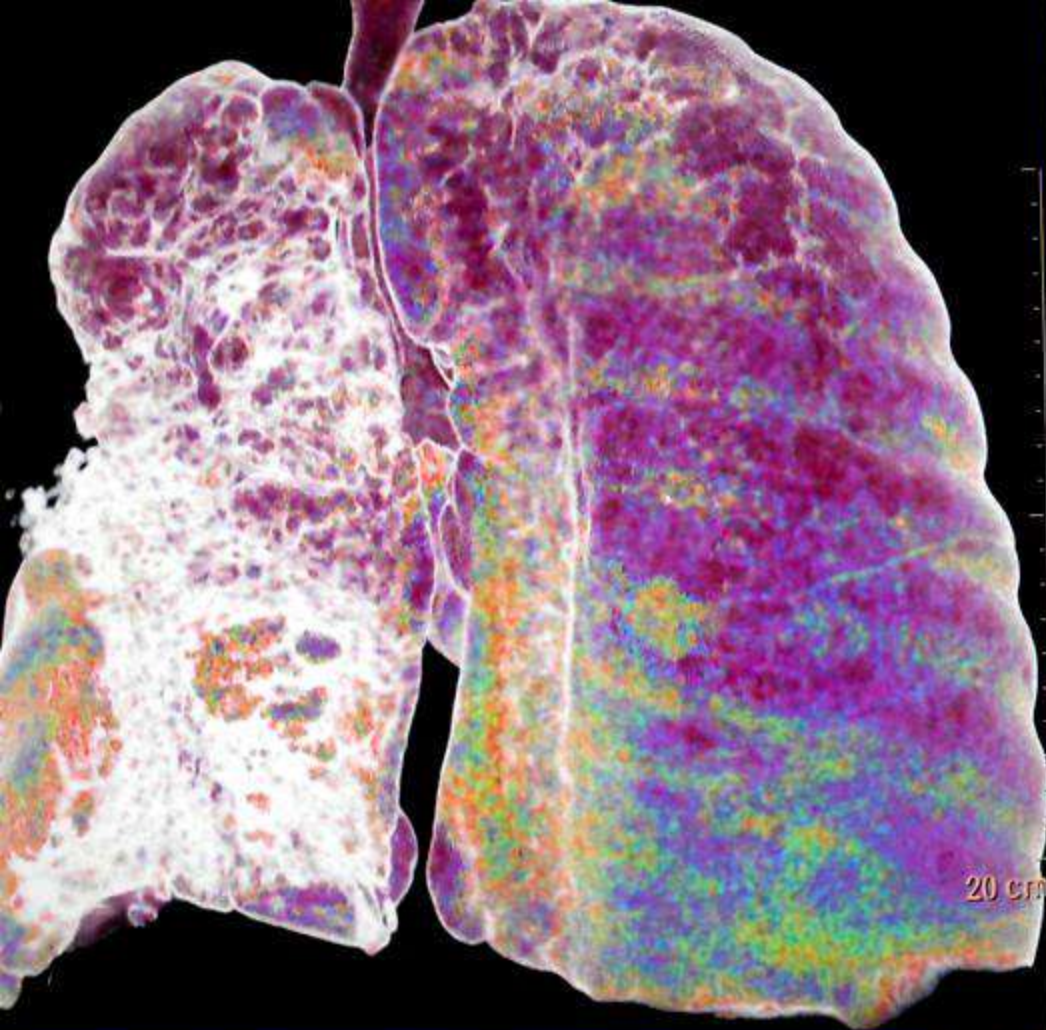
30 Jan, 2015 13:17:39

Z1

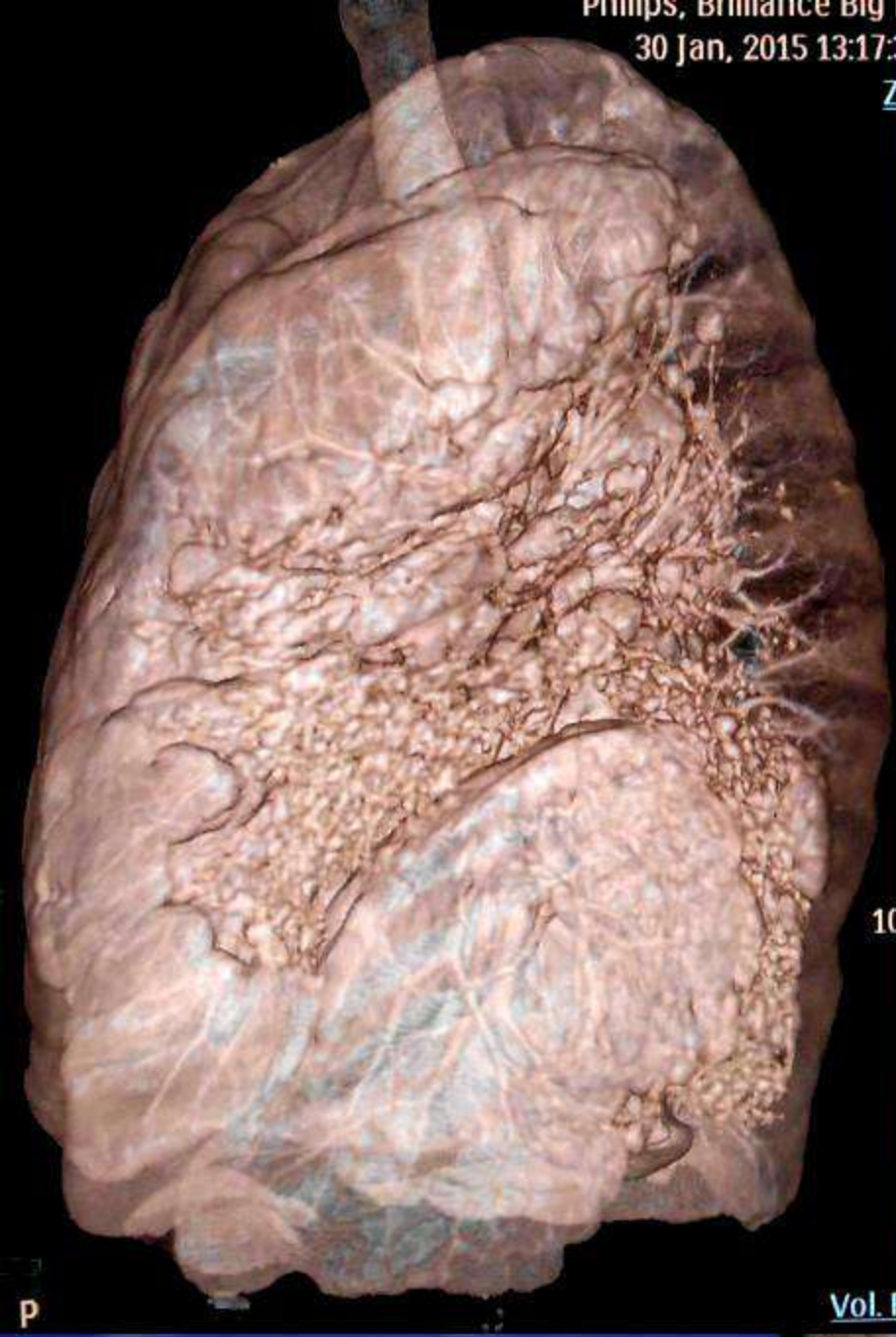

10



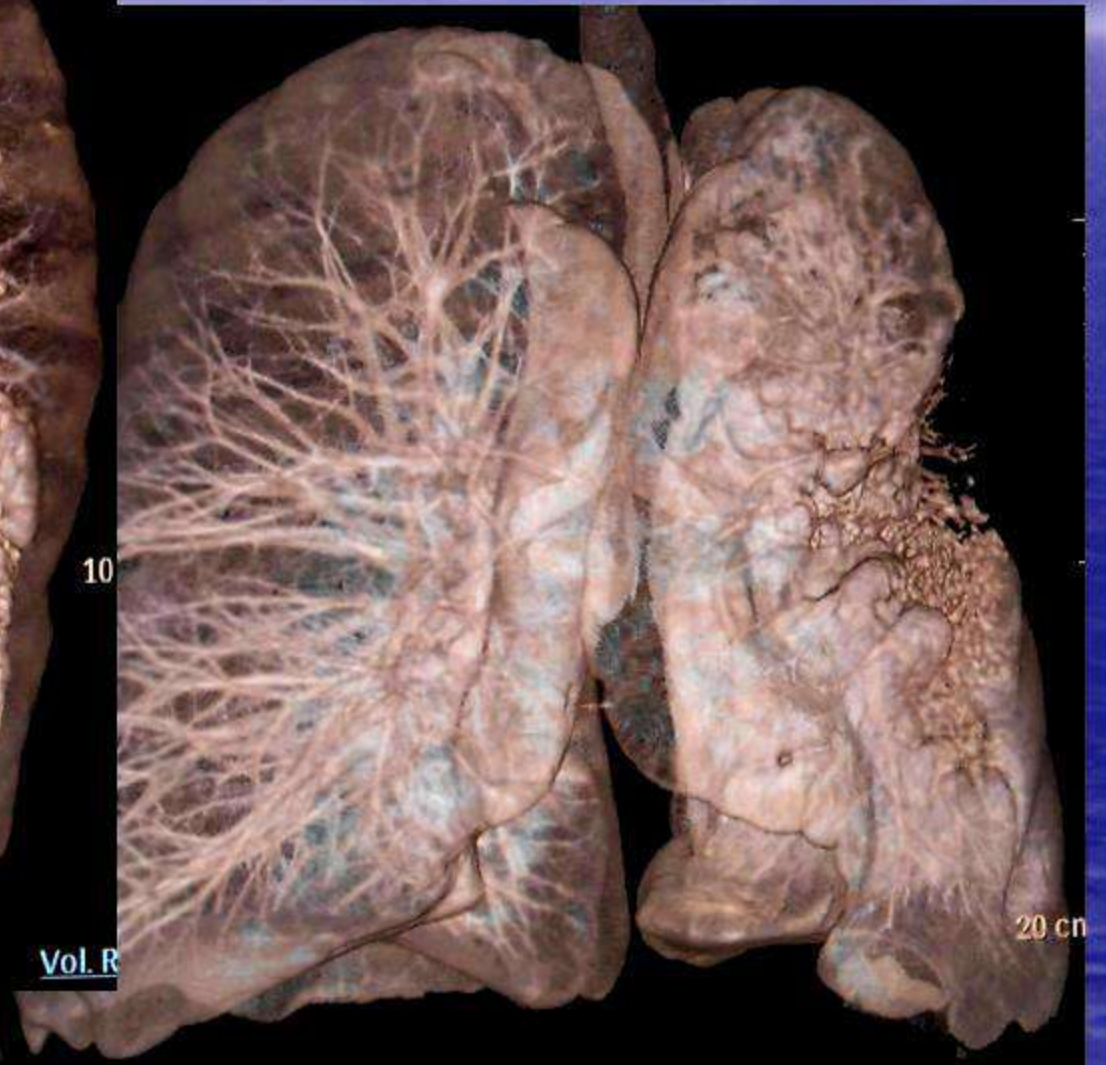

Z



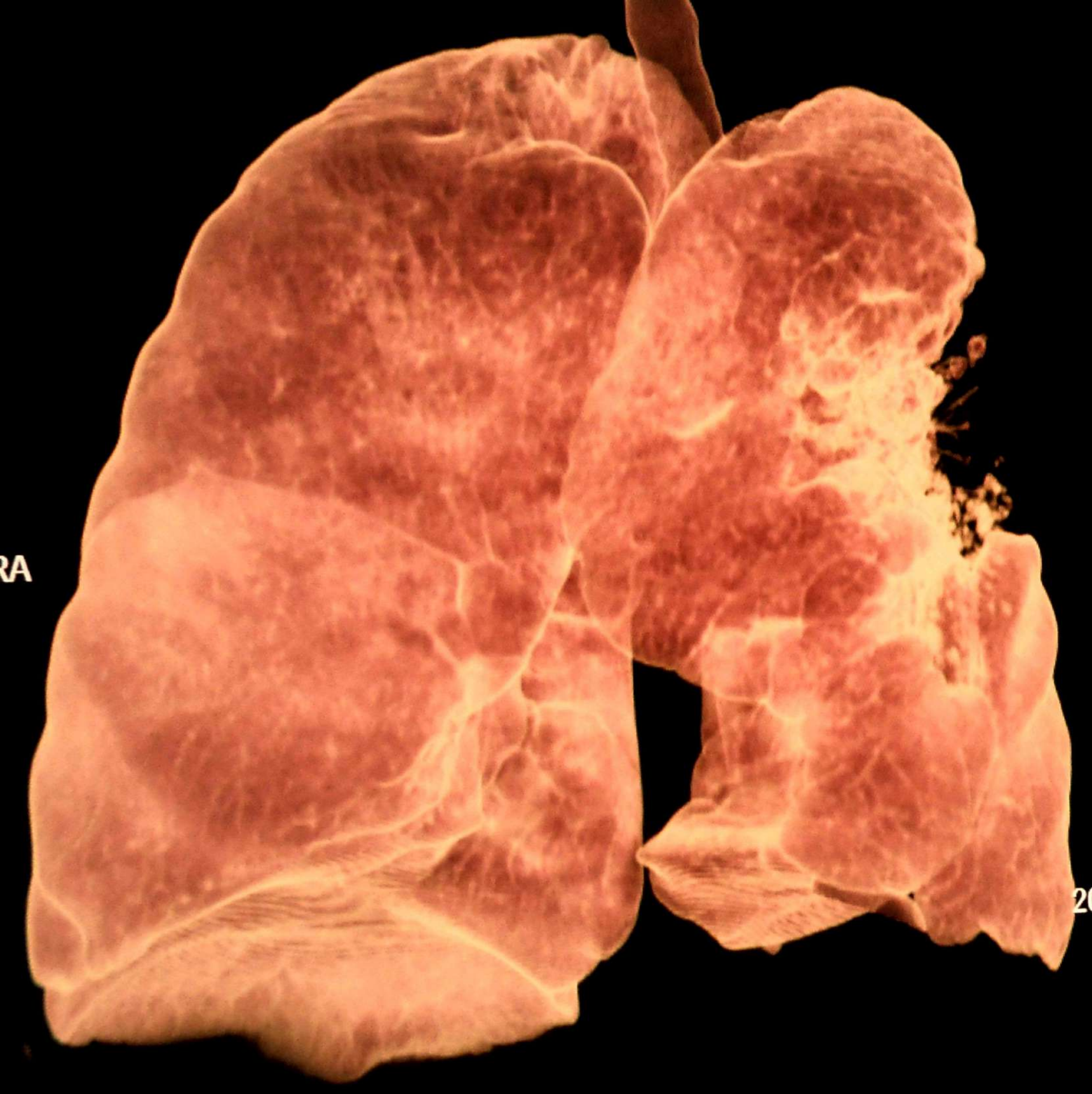10

Vol. R



20 cm

P



RA

20