

# Dental Multisection CT for the Placement of Oral Implants: Technique and Applications<sup>1</sup>

*Jaime A. Saavedra-Abril, MD • Claudia Balhen-Martin, MD • Kena Zaragoza-Velasco, MD • Eric T. Kimura-Hayama, MD • Santiago Saavedra, MD • Miguel E. Stoopan, MD*

## ONLINE-ONLY CME

See [www.rsna.org/education/lrg\\_cme.html](http://www.rsna.org/education/lrg_cme.html)

## LEARNING OBJECTIVES

*After reading this article and taking the test, the reader will be able to:*

- Discuss the important anatomic features and bone requirements for placement of a dental implant.
- Describe the multidetector CT protocol and postprocessing techniques for preoperative evaluation of dental implantation.
- List the information to be included in the radiology report for successful placement of dental implants.

## TEACHING POINTS

*See last page*

Dental computed tomography (CT) is a diagnostic examination for the preoperative evaluation of patients who will undergo placement of oral implants. It can be performed with multidetector CT or more recently with cone-beam CT. The growing older population and the consequent development of edentulism have increased the number of imaging studies performed for preoperative evaluation of dental implantation. Thus, radiologists are becoming more frequently involved in this type of testing. Dental CT is superior to conventional x-ray techniques because superimposition and distortion are eliminated; therefore, possible complications such as injury of the neurovascular bundle and perforation of the maxillary sinuses can be avoided. This noninvasive and fast method provides accurate information about the positions of important structures to allow one to determine the implant required. Dental CT enables analysis of the state, quality, and quantity of bone on two-dimensional and three-dimensional reformatted images, and its high spatial resolution allows exact measurements of the length and width of the alveolar ridge. Inclusion of all this information in the radiology report facilitates achievement of a successful implantation.

©RSNA, 2010 • [radiographics.rsna.org](http://radiographics.rsna.org)

RadioGraphics 2010; 30:1975–1991 • Published online 10.1148/rg.307105026 • Content Codes: **CT** **GN** **HN** **MK**

<sup>1</sup>From the Department of Radiology, Division of Computed Tomography, CT Scanner Lomas Altas, Paseo de la Reforma #2608, 6th Floor, Col. Lomas Altas, 11950 Mexico City, Mexico. Presented as an education exhibit at the 2008 RSNA Annual Meeting. Received February 12, 2010; revision requested April 27; final revision received July 1; accepted July 7. For this CME activity, the authors (J.A.S.A., C.B.M., K.Z.V., E.T.K.H., S.S.), editors, and reviewers have no relevant relationships to disclose. M.E.S. receives equipment support from GE Healthcare. Address correspondence to J.A.S.A. (e-mail: [jalsaavedra@cablevision.net.mx](mailto:jalsaavedra@cablevision.net.mx)).

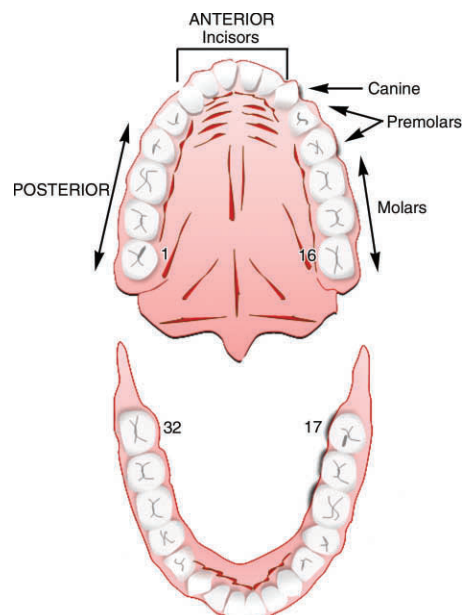
## Introduction

Partial or total edentulism is not only a cosmetic impairment but may substantially affect oral and general health as well as overall quality of life. Self-esteem, speech, and dietary intake are affected. It may also disturb food preference and taste with further poor consumption of dietary fiber. Alterations in dietary intake have been suspected to possibly increase the risk of cardiovascular disease and even cancer (1–4).

According to the World Health Organization, complete or partial absence of natural teeth is a public health problem with potential poor outcomes. It is a global issue, and the aging demographics indicate an increasing number of cases in the near future. Nowadays, approximately 30% of adults aged 65 years and older are edentulous. This figure is even higher for those living in poverty. Although the prevalence of complete or partial edentulism throughout the world is tending to decline (eg, from 46% 20 years ago), approximately 180 million Americans were affected by partial or complete edentulism in 2003 and about 9% of Canadians aged 15 years or older were edentate (total absence of teeth) (5,6). The estimated prevalence of edentulism in Mexico among the elderly is 30.6% (7).

Another factor associated with dental loss and mandibular bone resorption is osteoporosis, which deteriorates the mechanical function of mastication and thus creates a vicious circle. Likewise, dental loss and loose bridges or partial dentures impair proper masticatory forces that normally stimulate bone renewal, leading to osteoporosis of the alveolus (8). Prosthetic rehabilitation with osseointegrated implants supports the distribution of charges through mechanical propagation in a way similar to the physiologic patterns and has become the alternative of choice to a comfortable and functional denture.

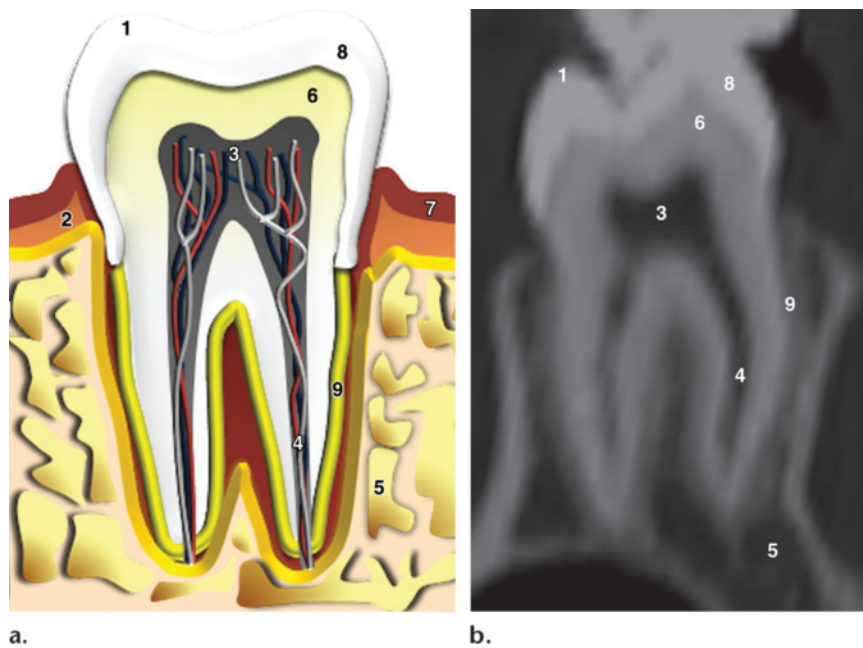
Radiographic evaluation is essential for assessing bony support for endosseous dental implants. Several intraoral and extraoral radiographic methods such as periapical, occlusal, panoramic, and motion tomography are commonly available for evaluation of the implant recipient site, but the information is based on bidimensional geometric projections (9). Some of the drawbacks of these techniques include superimposition, poor visualization of other anatomic structures, and distortion (10). There might be discrepancies in



**Figure 1.** Drawing shows the maxillary and mandibular arches with the permanent dentition. The 32 teeth are divided into quadrants containing eight teeth each: central and lateral incisors, canine, premolars, and molars (the third molar is also known as the wisdom tooth). The anterior and posterior zones are displayed. In the maxilla, the numbering system is from right to left (numbers 1–16); in the mandible, it is from left to right (numbers 17–32). The tooth surfaces are designated as (a) anterior or buccal (vestibular) surface for the maxilla and mandible and (b) posterior or palatine surface for the maxilla or lingual surface for the mandible. Finally, the terms *mesial* and *distal* are applied only to the mandible and represent the relationship of dental structures to the mental foramen. Mesial is anterior to the mental foramen (ie, toward the midline); distal is posterior to the mental foramen.

measurements compared with those from volumetric methods such as multidetector computed tomography (CT) or cone-beam CT, especially if the site of interest is less than 15 mm high.

Nowadays, the most accurate technique for preoperative evaluation of dental implantation is dental CT. Dental CT can demonstrate the quantity of bone in three dimensions, the location of important adjacent anatomic structures (eg, mandibular canal, dental inferior nerve, incisive foramen, mental foramen, maxillary sinus), and the quality of available bone with minimal geometric distortion (10).



**Figure 2.** Anatomy of a tooth. **(a)** Diagram shows the crown (1), gum (2), pulp (3), apical foramen (4), alveolar process (5), dentin (6), gingival margin (7), enamel (8), and periodontal ligament (9). The pulp is made up of vessels and nerves, which enter through the apical foramen. The alveolar processes are extensions of the maxilla and mandible that support the teeth. Dentin makes up the bulk of the tooth; it is covered by enamel on the crown and cement on the root. Enamel makes up the anatomic crown; it is the hardest material in the human body, incapable of remodeling or repair. The periodontal ligament is dense fibrous connective tissue that connects the tooth to the alveolar bone. **(b)** Corresponding CT image shows the crown (1), pulp (3), apical foramen (4), alveolar process (5), dentin (6), enamel (8), and periodontal ligament (9).

In this article, we define the normal anatomic landmarks and terminology used in preoperative evaluation for dental implantation, describe the technique of dental CT and postprocessing methods, illustrate the most important findings and measurements, and show incidental dental pathologic conditions. Finally, we discuss how this information is transferred to the radiology report.

### Anatomy and Terminology

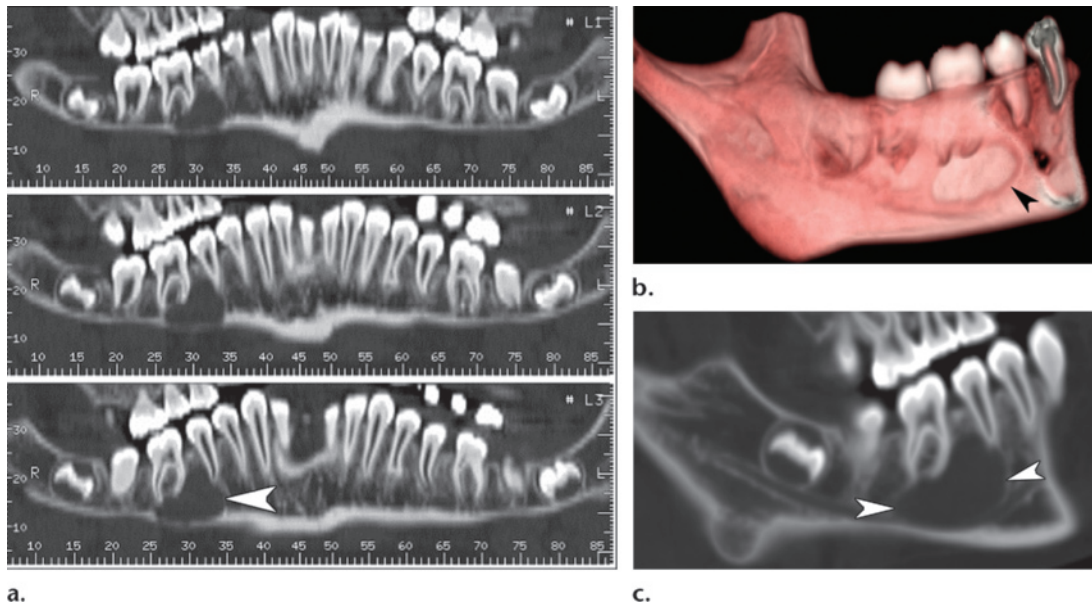
Permanent dentition appears between 6 and 21 years of age and consists of two incisors, one canine, two premolars, and three molars in each quadrant of the mouth (32 teeth total) (Fig 1). The standardized terminology used by dentists to locate and designate a tooth in the dental arch is based on numbers divided into quadrants, termi-

nology that the radiologist must know. There are different numbering methods; the most common and practical starts from the right side of the maxilla (last superior molar) and goes to the left upper quadrant (numbers 1–16), then continues from tooth number 17 in the posterior left side of the mandible to tooth number 32 in the posterior right side, forming a bow numeration or a circle out of the maxillary and mandibular arches. For example, tooth number 4 corresponds to the superior right second premolar.

The alveolar bone is the V-shaped bone containing the tooth sockets. The cement and the lamina dura are the strongest structures of the tooth and the cortical bone of the alveolus, respectively; the periodontal ligament attaches them (Fig 2). The neurovascular bundle enters the tooth at the root apex via the apical foramen. Dentin covers the pulp and is considered the living, growing part of the tooth from which enamel is produced. Enamel is the hard outer part of the tooth that is mineralized and forms the outer cover of the visible crown (11).

Teaching  
Point

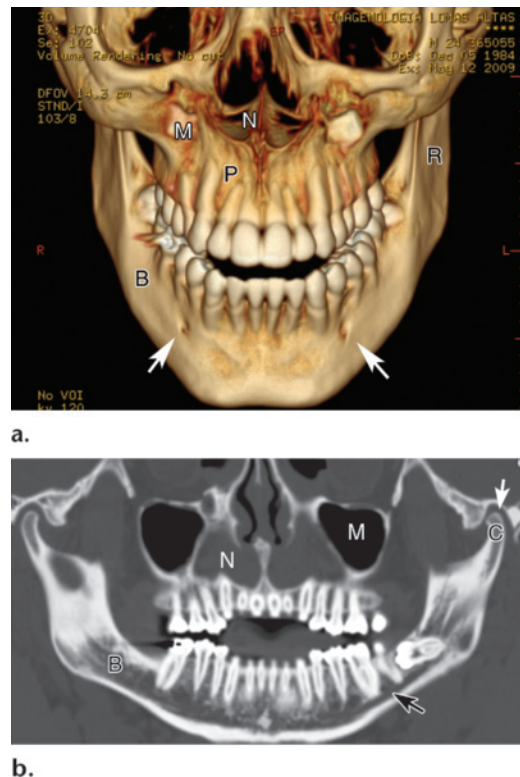
**Figure 3.** CT appearance of the teeth. (a) Dental CT images (panoramic or orthopantomographic reformatted view) show the normal appearance of the teeth. Note the circumscribed, well-corticated, radiolucent expansile lesion (arrowhead) in the posterior zone, adjacent to the roots of the first and second premolars on the right side of the mandibular body. Histopathologic analysis revealed an aneurysmal bone cyst. (b, c) Volume-rendered (b) and sagittal maximum intensity projection (c) CT images show the location of the lesion (arrowheads).



In x-ray techniques, such as conventional radiography, cone-beam CT, and multidetector CT, the enamel is the most opaque layer of the tooth, located in the upper part, followed by the dentin. The pulp and root canal in the central portion of the tooth appear less opaque. The periodontal ligament is generally not demonstrated at CT; therefore, an area of lucency around the teeth should alert one to a possible pathologic condition (Fig 3).

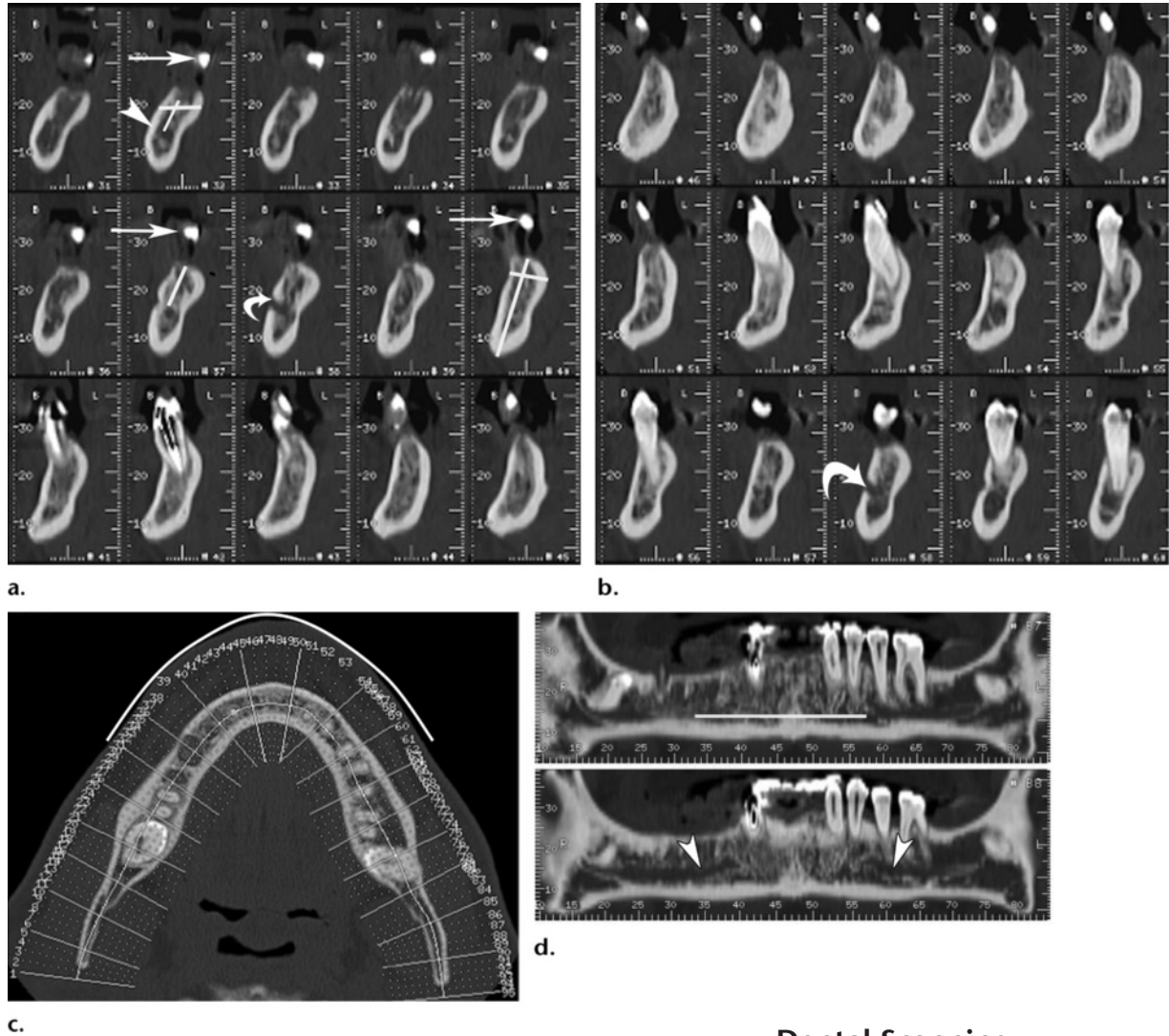
In regard to the mandible, it is important to depict the location of the inferior alveolar nerve or dental nerve, a branch of cranial nerve V3. It enters the mandible via the mandibular foramen, runs within the mental canal (either in the midline or at either side of the mandible) containing the inferior alveolar nerve and vessels, and exits the canal at about the level of the second premolars via the mental foramen (Fig 4) (11). The surgeon needs this information to avoid compression or sectioning of the nerve and to place fixtures in the optimal position (Fig 5).

The main arterial supply to the floor of the anterior mandible and gingival mucosa is the sublingual artery. This artery and its branches en-



**Figure 4.** Normal anatomy of the jaws. Volume-rendered (a) and panoramic (b) CT images show the nasal fossa (N), alveolar recess of the maxillary sinus (M), palate (P in a), body of the mandible (B), mental foramina (arrows in a), ramus of the mandible (R in a), condylar head (C in b), glenoid fossa (white arrow in b), and inferior alveolar canal (black arrow in b).

**Figure 5.** Evaluation of the inferior alveolar canal. **(a, b)** Cross-sectional CT images of the mandible show the right and left mental foramina (curved arrow, images 38 and 58). The images were reformatted along the numbered perpendicular lines shown in **c**, which are based on the superimposed curves placed in an axial image at the level of the roots of the teeth or along the contour of the maxilla or mandible. Measurement of the inferior alveolar canal (arrowhead in **a**) has to be performed from the superior border of the alveolar canal to the alveolar ridge, which is slightly concave. Straight arrows in **a** = markers placed by the dentist. **(c)** Axial CT image shows the range of the cross-sectional images included in the study (curved white line). **(d)** Panoramic CT images of the mandible show the right and left mental foramina (arrowheads). Straight white line = range of the cross-sectional images included in the study.

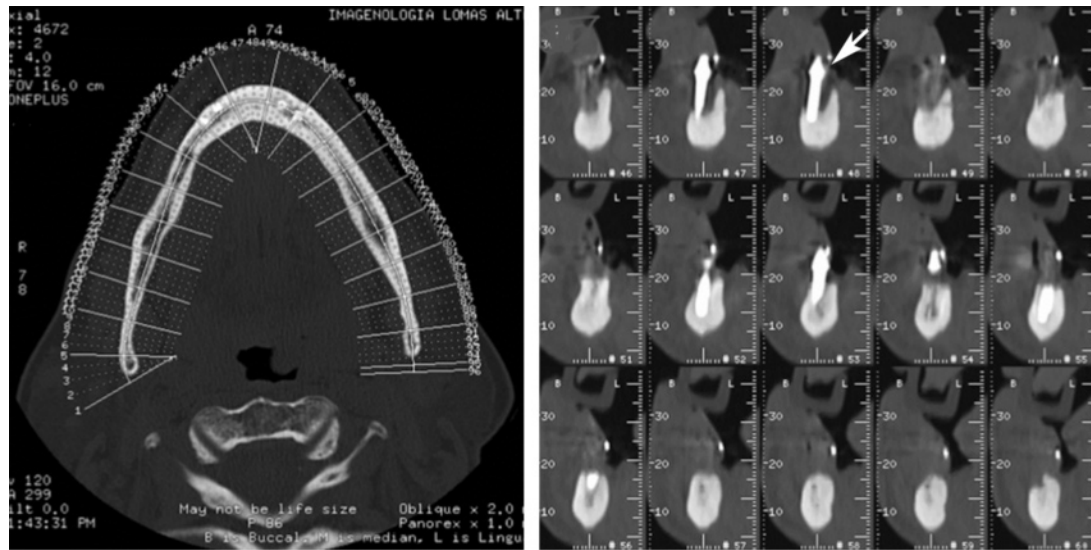


ter the mandibular foramen and accompany the inferior dental nerve but do not exit through the mental foramen. A lingual vascular canal larger than 1 mm is more prone to hematoma formation (12).

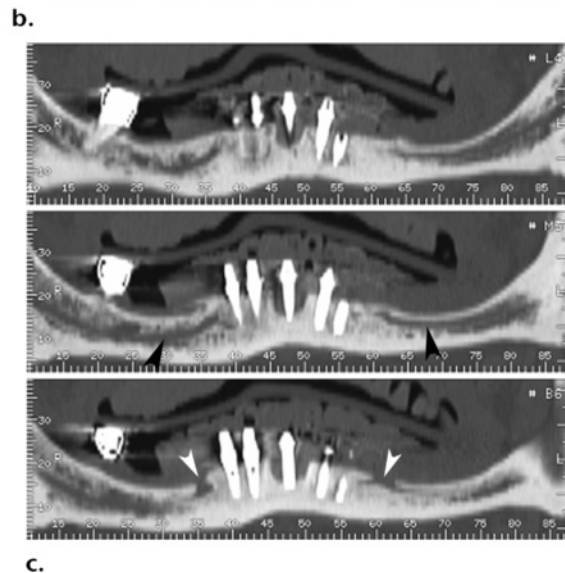
Finally, other important dental anatomic terminology is described in Figure 1.

### Dental Scanning

In presurgical assessment of a potential implant site, the state and quality of the bone are among the most important criteria for the surgeon. Evaluation of bone support, mass, and height can be achieved with a variety of imaging modalities. A



**a.**  
**Figure 6.** Osseointegration failure of a central implant fixture in a partially edentulous patient. **(a)** Axial CT image shows the body and rami of the mandible and the roots of the teeth. The technologist usually selects a plane where these structures are best shown and defines a curve to produce cross-sectional oblique and panoramic reformatted images. **(b)** Cross-sectional oblique CT images show bone loss around a central implant (arrow, image 48) and decreased height of the alveolus. **(c)** Panoramic CT images show the relationship of the implant to other structures, including contiguous implants. The inferior alveolar canal (black arrowheads) is well depicted in image M5; note that the nerve is near the superior cortical bone due to atrophy. The mental foramina lie superiorly on the alveolar crest (white arrowheads) in image B6.



conventional x-ray technique, such as periapical, occlusal, and panoramic radiography, is a simple, low-cost, and still frequently used method, but the information provided might be insufficient. Geometric distortion occurs in about 25% of studies, since the plane parallel to the beam superimposes structures. In addition, this method cannot demonstrate opacity differences of less

than 10% and does not provide details about the adjacent anatomy (9).

High-resolution dental CT (13,14) can generate panoramic, cross-sectional, and three-dimensional reformatted images of the alveolar bone and adjacent structures (Figs 5, 6), providing accurate information about bone height and width of the alveolar ridge to determine the alternatives for dental implantation. **The advantages of dental CT include elimination of superimpositions. It also allows distinction of opacity differences between two tissues (ie, contrast resolution), and further image projections or planar reformations can be performed (9).** Dental CT can be

**Teaching  
Point**

achieved with multidetector CT or more recently with cone-beam CT (15–18).

### Indications and Contraindications

The most relevant indications for dental CT in preoperative evaluation of dental implant placement (listed in order of importance) are as follows: (a) assessment of height and thickness in cases of alveolar bone atrophy (19); (b) assessment of the positions and states of the structures critical for adequate implant placement (eg, inferior alveolar canal, location of the neurovascular bundle and the incisive and mental foramina, pneumatization of the maxillary sinus, floor of the maxillary sinus, nasal fossa); (c) diagnosis and treatment in maxillofacial surgery; (d) examination after placement of implants and bone grafts; and (e) evaluation of bone resorption and root retention, as well as lesions of the facial skeleton. The main contraindications include claustrophobia, Parkinson disease, tremors and tics, and disabling conditions that might cause a patient to be uncooperative.

### Data Acquisition and Postprocessing

The information presented herein was obtained between January 2002 and May 2008 from 441 dental studies performed in patients who were referred for preoperative evaluation for dental implant placement. The studies were performed with a four- or 64-row multisection CT scanner. Imaging was performed with the patient supine and with the head centered and immobilized by using a jaw strap or sponge pads on each side of the temporal region. Patients were instructed not to move, swallow, or chew during the acquisition process. An anatomic buccal protector was used opposite to where the implant would be placed to allow separation of the adjacent tooth crowns.

Data acquisition was performed parallel to the alveolar crests to allow better orientation of the cross-sectional images, since different transaxial planes may cause incorrect height measurements of the bone for implant placement (15). Axial images were obtained with the following param-

eters: detector coverage of 40 mm per rotation,  $512 \times 512$  matrix with a 16-cm field of view, section thickness and separation between sections of 0.6 mm (64-row scanner) or 1.25 mm (four-row scanner), low pitch of 0.516:1, and rotation time of 0.35 seconds (64-row scanner) or 0.6 seconds (four-row scanner). Initially, two reconstructions were performed: one with a standard filter and one with a bone filter. Both sets of images were processed with dental software to create panoramic and sagittal oblique (cross-sectional) reformatted images of the maxilla and mandible (20).

One of the drawbacks of multidetector CT is radiation dose, which has been an issue of concern. Several factors including section thickness, intersection interval (pitch), kilovoltage, and milliamperage must be considered during the examination. The magnitude of the biologic risk of diagnostic x-ray studies depends on the radiation and dose rate, the volume and radiosensitivity of the tissue, and patient characteristics, primarily age (21,22). Although most of the edentulous population is older than 40 years, there might be younger patients who require dental restoration, mostly due to trauma. Highly radiosensitive organs are near the area of exposure, such as the thyroid gland, parotid gland, bone marrow, and lens of the eye (23).

Effective radiation dose can be reduced without loss of anatomic detail by using low kilovolt peak and milliamperage settings. We use two different techniques: If the patient has few or no amalgams, dental fillings, or prostheses that could cause artifacts due to metal, we usually use a tube potential of 100 kVp and tube current of 200 mA. However, if the patient has many restoration amalgams (most common situation), we use a tube potential of 120 kVp and tube current as high as 350 mA (average, 300–310 mA) with automodulation; the total effective dose can range from less than 1 mSv to 2–4 mSv. In addition, a sequential acquisition (ie, step-and-shoot technique) and a low-dose protocol as described by Suomalainen et al (24,25) can be used to further reduce the effective radiation dose.

On the other hand, although cone-beam CT has been in use for almost 2 decades, affordable systems have become commercially available only recently. Therefore, cone-beam CT has emerged as a low-cost and low effective radiation dose imaging tool for three-dimensional craniofacial exploration (15). Cone-beam CT scanners are based on volumetric tomography and use a collimated, narrow, cone-shaped x-ray beam instead of the fan-shaped geometry of multi-detector CT. Image data are recorded during a single 360° video scan in which the x-ray source and a reciprocating two-dimensional detector synchronously move around the patient's head (15). Some of the advantages of cone-beam CT are isotropic voxels with a spatial resolution of 0.125–0.4 mm and a more restricted field of view that limits the radiation dose with detector array sizes of 4–22 cm (15,16). Typically, the total data acquisition is performed in 10–70 seconds with a mean effective radiation dose of 36–50  $\mu$ Sv, a value equivalent to that of four to 15 panoramic radiographs (15–17).

In summary, both multidetector CT and electron-beam CT are volumetric imaging methods that can be used in preoperative evaluation for dental implant placement. The main difference between these methods is that multidetector CT provides higher contrast-to-noise and signal-to-noise ratios than cone-beam CT but at the expense of higher radiation exposure. However, low-dose multidetector CT protocols (tube potential of 100 kV) with use of sequential acquisitions rather than the helical mode may significantly reduce the effective radiation dose.

Once the axial images have been obtained, the dental software program is performed on a dedicated workstation. The raw data from the axial sections are used to create (a) superimposed curve images (curved planar reformation), (b) panoramic images, and (c) sagittal oblique images.

**Superimposed Curve Images.**—Initially, a curve is superimposed on one of the axial images of the maxilla or mandible, thus defining the plane and location for reformation of the panoramic and

sagittal oblique images. The axial image must be obtained approximately at the level of the tooth roots; in patients with edentulism, it should be obtained where the gum of the mandible or maxilla is shown completely (23). The curve is obtained by positioning several contiguous points throughout the center of the mandible or maxilla by using the pointer of the workstation console; the program connects the points shown on the curve (23) (Figs 5, 6).

The perpendicular lines marked along the superimposed curve indicate the positions of the sagittal oblique reformatted images on the axial section and the levels of the reformatted images, thus providing data on the height and depth of every image. The numbering of these lines starts in the right posterior zone and ends in the left posterior zone. Such parameters may vary slightly from program to program (26) (Figs 5, 6).

**Panoramic Images.**—The panoramic images are created on the basis of the superimposed curve, which is labeled with the letter *M* (for midline) in the left upper quadrant (Fig 6). From this reformation, four images are displayed from back to front on either side of the midline, for a total of nine images with a section thickness of 1 mm and a 1-mm interval. The first four images (ie, those posterior to the midcurve, which is labeled *M5*) are labeled *L1–L4* (*L* for lingual relative to the maxilla or mandible) (Figs 6, 7). The last four images (those anterior to the center) are labeled *B6–B9* (*B* for buccal relative to the maxilla or mandible) (27).

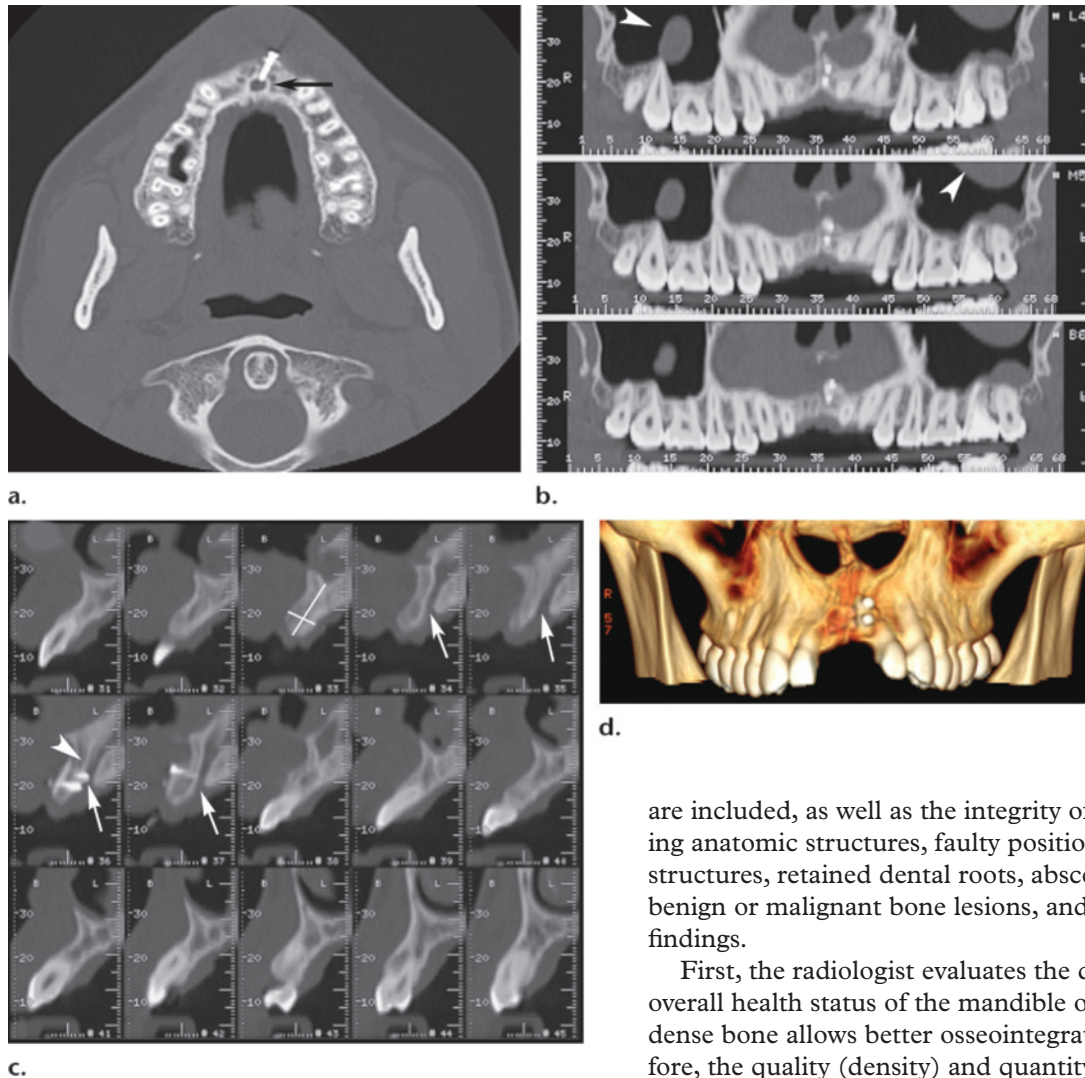
**Sagittal Oblique Images.**—The sagittal oblique images are the most representative and important images in dental CT, since the shape, angulation, and measurements of height and thickness of the alveolar bone are determined on the basis of these images (20). They allow the surgeon to define the optimal fixture lengths required to engage the cortical bone and the remaining distances from vital structures. These images are obtained from multiple 1-mm-thick sections with a 2-mm interval that are orthogonal to the superimposed curve (*M5*) (Fig 5). The images are numbered from right to left, and 100 images are typically generated (Figs 5, 6) (28).

Teaching Point

Teaching Point



**Figure 7.** Traumatic loss of the central incisors in a 13-year-old patient. An autologous corticocancellous block bone graft with an apicoronal orientation was placed at the site of the left central incisor to augment the bone and permit implant placement. **(a)** Axial CT image shows a titanium osteosynthesis fixation screw with an oblique orientation to the incisive foramen (arrow). **(b)** Panoramic CT images of the maxilla show the locations of the lost teeth and the site of the bone graft. There are also polyps in both maxillary sinuses (arrowheads). The numbering of the images is from back to front: image L4 is the lingual surface, image M5 is the site of the superimposed curve or midline, and image B6 is the vestibular surface. **(c)** Cross-sectional CT images show a 3-mm radiolucent space between the failed autograft and the resorbed alveolar bone of the left central incisor (arrowhead, image 36). The crossed white lines indicate how measurements are performed (image 33). Arrows = incisive foramen (images 34–37). The surgeon decided not to place an implant because of the atrophic alveolus and the failed bone graft. **(d)** Volume-rendered CT image of the maxilla shows the final result.

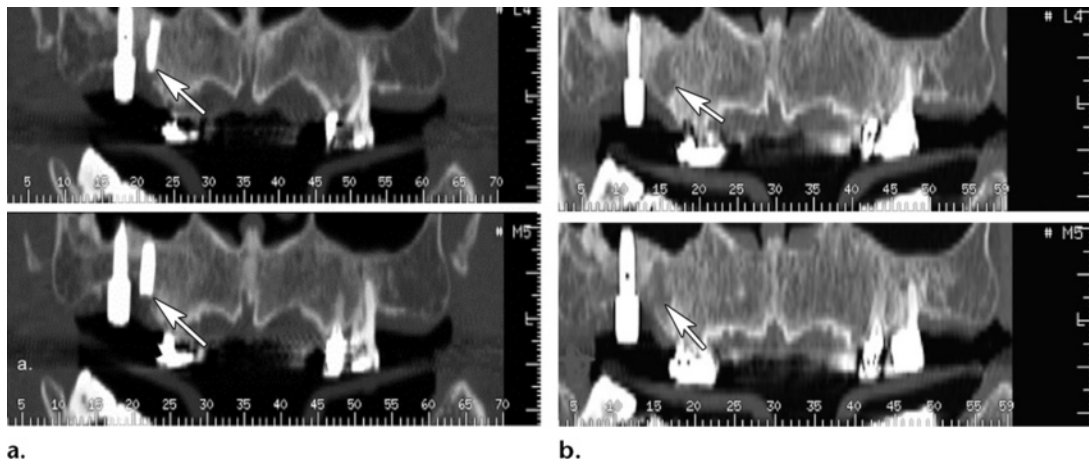


### Radiology Report

The radiology report must be complete and comprehensive. In summary, the bone density and the width and height of the alveolar process

are included, as well as the integrity of underlying anatomic structures, faulty positions of dental structures, retained dental roots, abscesses, benign or malignant bone lesions, and incidental findings.

First, the radiologist evaluates the density and overall health status of the mandible or maxilla. A dense bone allows better osseointegration; therefore, the quality (density) and quantity (height and width) of the alveolar bone must be assessed to choose the best implant size and placement technique for the patient. Implant performance is closely related to load transmission at the bone-implant interface; decreased size and density of



**Figure 8.** Implant failure. **(a)** Panoramic CT images show a fractured dental implant (arrows). **(b)** Follow-up CT images show complete removal of the implant (arrows).

the alveolar process are associated with higher failure rates (Fig 8). After edentulism, mineral loss from the cancellous part of the alveolar bone occurs before loss of crest height (9); that is, resorption first affects bone width and later bone height, except in the posterior zone of the superior maxilla, where atrophy predominantly affects bone height (27). The grade of resorption influences the size of the implant to be placed. The changes in bone quality (density) of the alveolar process influence its load-bearing capacity. Several scales have been used to determine bone quality. The most representative are shown in the Table (29–31) (Fig 9).

All contours, dental extractions, maxillary sinus disease (Figs 7, 10, 11), periodontal disease (Fig 10), retained dental roots, abscesses, and cysts (Fig 3) are included in the report. Surgical changes (Figs 7, 8, 10) and abnormalities such as torus palatinus or torus mandibularis must also be reported.

Partial or complete absence of teeth (edentulism) and the locations of partial edentulism are described. Measurements are obtained approximately every four sagittal oblique images (with a 2-mm space between images) in the areas of interest. To decrease the probability of dental implant failure, it is estimated that the bone implant site needs to be at least 9 mm high and 5 mm wide (25). In addition, the minimum required distance from the implant to the adjacent cortical bone is 1 mm; the minimum required distance from the implant to contiguous dental or implant pieces is 1.5 mm (27).

### Bone Quality Indexes

#### Cawood and Howell (29)\*

- Grade 1 corresponds to dentate bone
- Grade 2 occurs immediately after tooth extraction; the alveolar crest is mostly retained with a rounded shape
- Grade 3 is a rounded crest; both height and width are preserved
- Grade 4 is a knife-edge crest with normal height and width
- Grade 5 is a flat crest with abnormal height and width
- Grade 6 is a depressed crest with variable basal bone loss

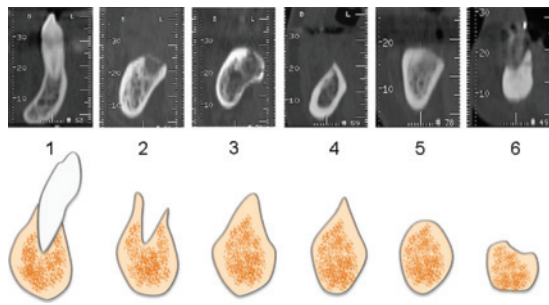
#### Lekholm and Zarb (30)†

- Type 1 is compact bone
- Type 2 is compact and trabecular bone
- Type 3 is a thinner cortical layer with fine trabeculae
- Type 4 is thin cortical bone surrounded by trabecular bone of low density

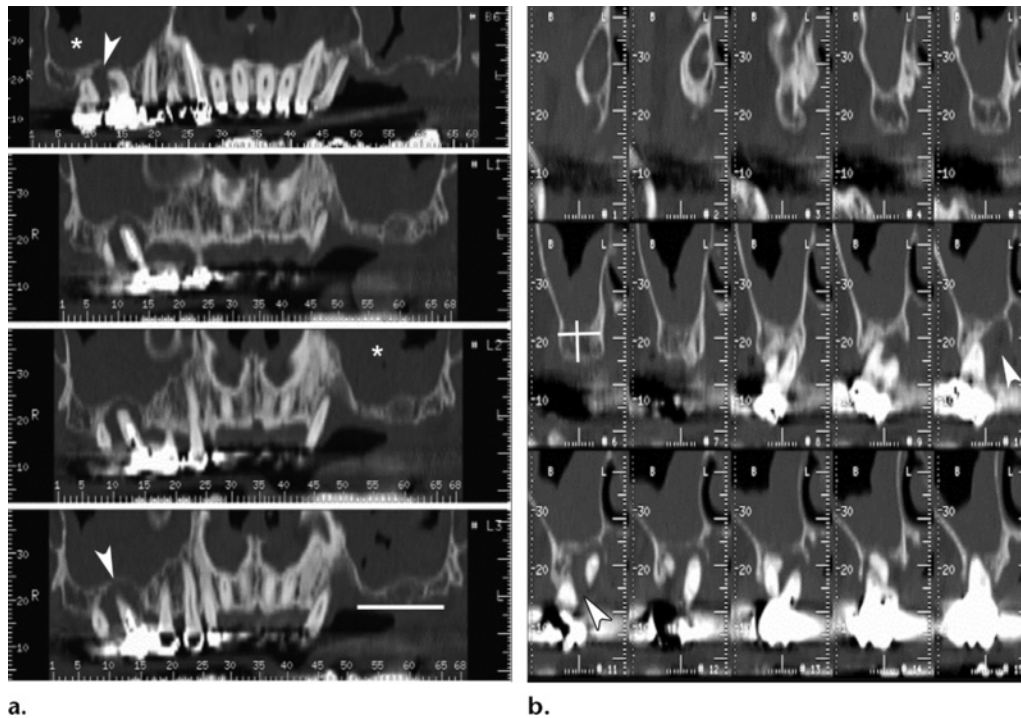
#### Norton and Gamble (31)‡

- Quality value 1 is >850 HU
- Quality values 2 and 3 = 500–850 HU
- Quality value 4 = 0–500 HU

Note.—Numbers in parentheses are references.  
 \*This scale is based on volume loss (height and width). In the different stages of alveolar atrophy, height is respected through grade 4; in the final stages (grades 5 and 6), the bone of the crest becomes flat with further depression of the basal bone.  
 †This subjective scale is based on bone density. Types 1 and 2 are often found in anterior and lateral zones of the mandible; type 4 is observed in the posterior zone of the maxilla after a long period of edentulism. Implants in type 4 bone require a longer cicatrization time and have a higher failure risk.  
 ‡This objective scale is based on measurements in Hounsfield units. A bone attenuation value of at least 600 HU has been cited as ideal for implants.

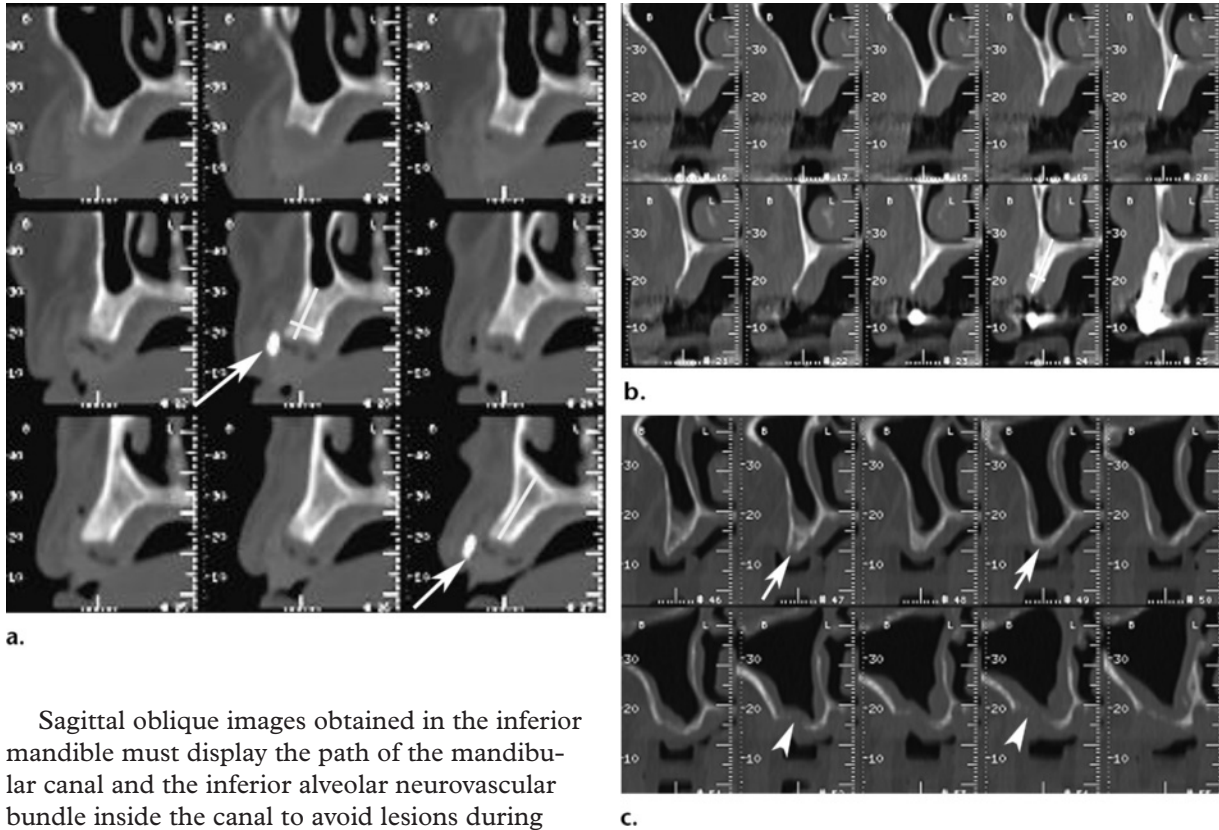


**Figure 9.** CT images and drawings of the mandible show the classification of alveolar bone atrophy of Cawood and Howell (29). Grade 1 is a normal alveolar crest with the tooth in place. After edentulism, alveolar crest atrophy begins, first in width and then in height. Grade 2 is mild atrophy of the alveolar crest. Grade 3 is a rounded alveolar crest; both height and width are preserved. Grade 4 is a knife-edge crest with normal height and width. Grade 5 is a flat crest with abnormal height and width. Grade 6 is a depressed crest with variable basal bone loss.



**Figure 10.** Periodontal abscess in a partially edentulous patient with endodontic obturation and permanent restoration of the upper right first molar. **(a)** Panoramic CT images show a periodontal abscess (arrowheads), which appears as a round area of soft-tissue attenuation at the apex of the root. Significant bilateral thickening of the maxillary sinus mucosa is seen (\*). **(b)** Cross-sectional CT images show erosion of the palatine cortex of the maxilla and maxillary sinus floor (arrowheads) due to the periodontal infection. Note the decreased bone density and height of the alveolar ridge (crossed white lines, image 6).

**Figure 11.** Alveolar bone atrophy of the maxilla according to the classification of Cawood and Howell (29). **(a)** Cross-sectional oblique CT images show grade 2 atrophy. The width and height of the alveolar ridge at the level of the premolars and premaxilla are preserved. The measurements were performed at the level of markers placed by the dentist (arrows). **(b)** Cross-sectional oblique CT images show vestibulopalatine atrophy with a knife edge (grade 4) (images 21 and 22). **(c)** Cross-sectional oblique CT images show severe bone atrophy (grade 6) due to a long period of dental loss. The decreased height and width of the alveolar ridge (arrows) are associated with depression and even destruction of the basilar bone (arrowheads). A chronic inflammatory process at the floor of the maxillary sinus is also evident.



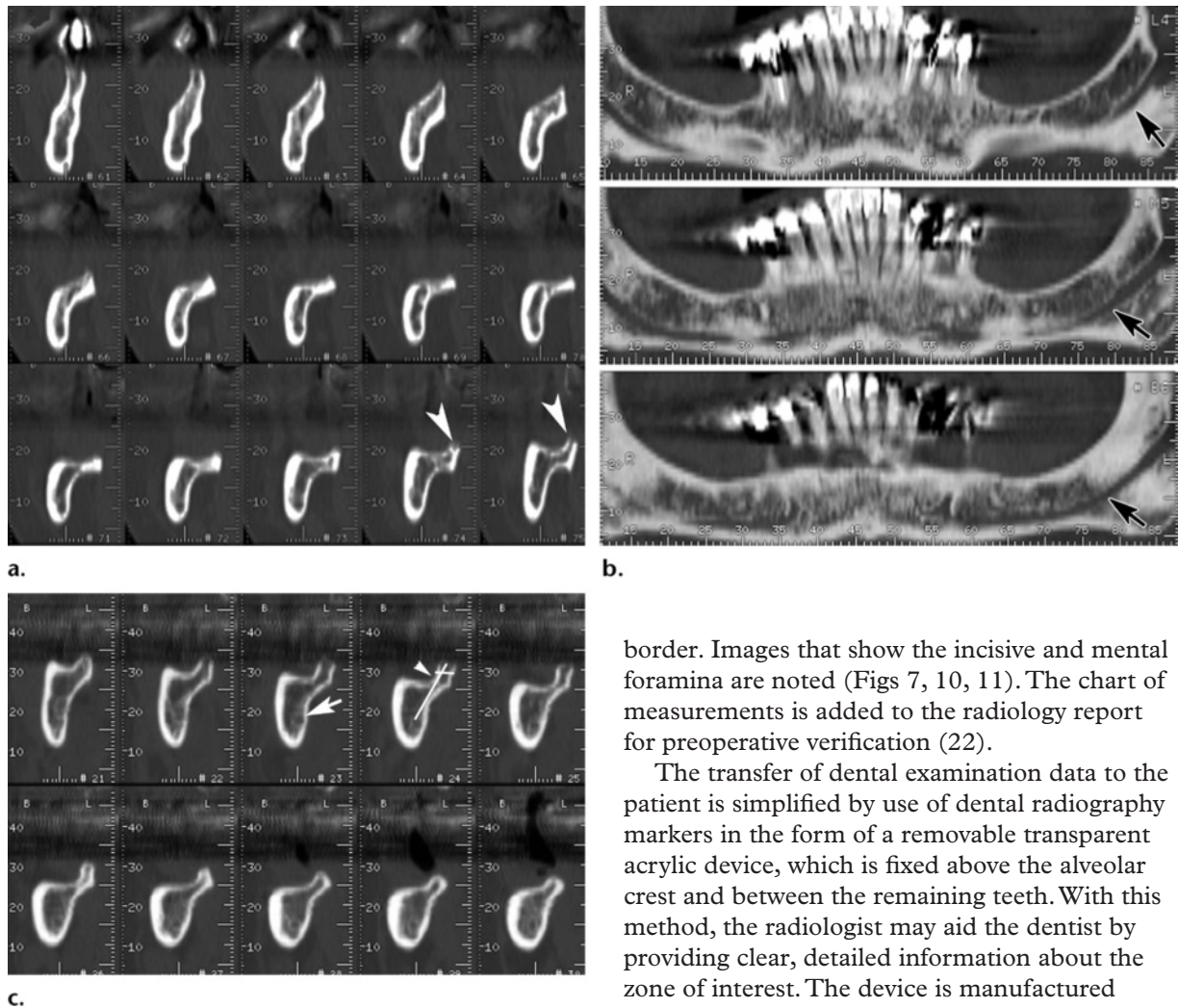
Sagittal oblique images obtained in the inferior mandible must display the path of the mandibular canal and the inferior alveolar neurovascular bundle inside the canal to avoid lesions during implantation. To accomplish this, the measurements must be obtained in a parallel plane from the superior border of the inferior alveolar canal to the alveolar ridge (Fig 12). The canal is often seen as an oval, thin rim of dense cortical bone around the nerve. The measurements have to be obtained approximately as far as the level of the canines, since the nerve ends in the mental foramen, which is usually at the level of the canines; these measurements do not apply to the area mesial to the mental foramen.

When studying the path of the inferior dental nerve in the mandibular canal for the collocation of implants, radiologists usually place the reference plane parallel to the inferior ridge of the horizontal mandibular branch. As a result,

the sagittal oblique sections show the distance between the bone crest and the nerve before it reaches its end in the mental foramen (for measurements distal to the mental foramen) (28). The height of the mandibular bone or of residual teeth distal to the mental foramen (premolars and molars) must be measured from the uppermost section of the alveolar canal to the uppermost portion of the alveolar process (bone crest) (Fig 5) (28).

The bone thickness (vestibule-lingual distance) is measured as the area of minimal disposable bone that will limit the size of the implant. The measurement is made at the uppermost portion of the alveolus from the vestibular (facial or buccal) surface to the lingual cortical surface.

**Figure 12.** Cross-sectional (a) and panoramic (b) CT images of a patient with vestibulolingual atrophy (ie, decreased width of the mandible) and (c) cross-sectional CT images of another patient with vestibulolingual atrophy show a concave upper border (arrowheads in a [images 74 and 75], arrowhead in c [image 24]). The inferior dental canal is clearly seen (arrows in b, arrow in c). The height measurement is made from the inferior dental canal (distal to the mental foramen) to the alveolar ridge (diagonal white line in c).



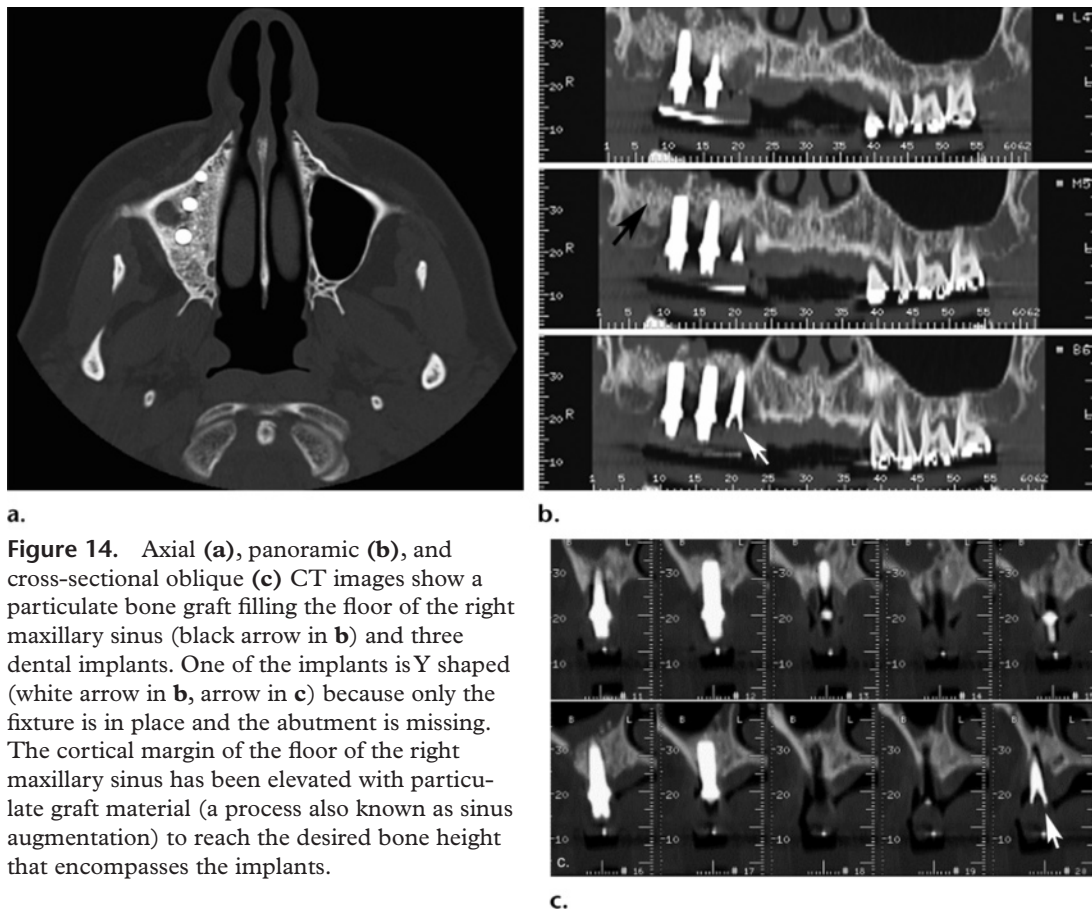
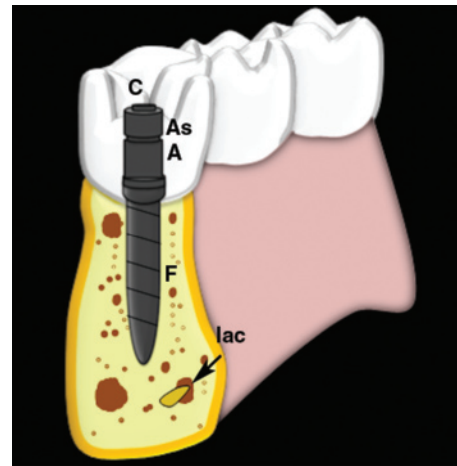
In general, if this measurement is smaller than 4 mm, it will be reported as vestibulolingual atrophy (Fig 12) (27).

At the mesial (anterior) level of the maxilla, the measurements are made from the alveolar crest to the floor of the nasal fossa, thus preserving the nasopalatine canal. The height of the bone in the posterior region is measured from the floor of the maxillary sinus to the inferior alveolar ridge. The width is measured in the same way as in the mandible, from the inner vestibular cortical border to the inner palatine cortical

border. Images that show the incisive and mental foramina are noted (Figs 7, 10, 11). The chart of measurements is added to the radiology report for preoperative verification (22).

The transfer of dental examination data to the patient is simplified by use of dental radiography markers in the form of a removable transparent acrylic device, which is fixed above the alveolar crest and between the remaining teeth. With this method, the radiologist may aid the dentist by providing clear, detailed information about the zone of interest. The device is manufactured by the dentist using a mandibular or maxillary impression that contains radiopaque markers, usually of gutta-percha. The markers must be 1–2 mm in diameter with a vertical orientation, with no mesial or distal inclination. Ideally, the markers are fixed to the gingival surface and placed inside the buccal sulcus. The markers appear as radiopaque structures on the axial, panoramic, and sagittal oblique images. The canine must be identified as a mesial orientation point of the markers. On sagittal oblique images, the

**Figure 13.** Osseointegrated dental implant. The body or fixture (*F*) of a dental implant is placed in the mandible, sparing the inferior alveolar canal (*Iac*). It is connected to the abutment (*A*) and secured by an abutment screw (*As*). The prosthetic crown (*C*) has a linkage screwed to the abutment.

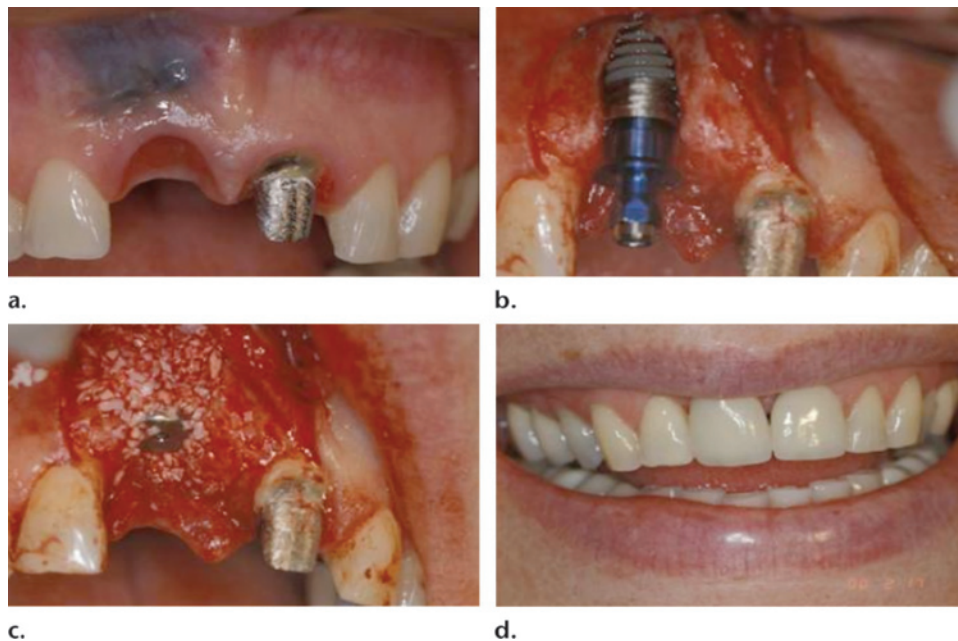


**Figure 14.** Axial (**a**), panoramic (**b**), and cross-sectional oblique (**c**) CT images show a particulate bone graft filling the floor of the right maxillary sinus (black arrow in **b**) and three dental implants. One of the implants is Y shaped (white arrow in **b**, arrow in **c**) because only the fixture is in place and the abutment is missing. The cortical margin of the floor of the right maxillary sinus has been elevated with particulate graft material (a process also known as sinus augmentation) to reach the desired bone height that encompasses the implants.

gutta-percha markers indicate the exact location planned for placement of the implant, with the bone height and thickness measurements of the alveolus shown on the images (Fig 11).

## Dental Implants

Dental implants are composed of titanium, which fuses with the jawbone by means of growth of osteoblasts, a process called osseointegration. The implant and the bone are allowed to bond, and



**Figure 15.** Dental implant placement in a 46-year-old woman. **(a)** Photograph shows loss of the superior right central incisor and a metal crown in place of the superior left central incisor. **(b)** Photograph shows a dental implant placed at the location of the superior right central incisor. Later, this area was packed with a particulate graft to cover the implant and a collagen membrane to cover the screw and promote osseointegration. **(c)** Photograph shows that the abutment of the implant is visible. **(d)** Photograph shows the final outcome after placement of a restorative crown on the implant. (Case courtesy of Israel Speckman, DDS, Mexico City, Mexico.)

the implant is imbedded in the edentulous area to provide anchorage for a dental prosthesis. A dental implant has a cylinder or screw configuration and functions as the root of a tooth (Fig 13).

The success rate of implant integration depends on the length of the implant—the longer the better. The implant being placed must be as long as the height of the bone and as long as the structure of the implant allows it to be, since maximum mechanical and contact area for osseointegration is the final goal (28). If there is significant atrophy, augmentation of the available bone (cortical expansion, sinus elevation, bone graft, anchorage of the implant to another site specifically in the pterygomaxillary or malar region) is considered (Figs 7, 14, 15).

Other factors important to a good dental implant outcome include ensuring that the bone is adequate and that there is no periodontal disease. In addition, the patient must practice good oral hygiene and avoid irritative factors such as smoking (32).

A lost tooth is replaced with an implant, and two teeth are replaced with two implants. However, three or more lost teeth do not necessarily require replacement of each tooth with an implant if the quality and quantity of bone available are adequate. The surgeon might place two implants on the ends with a crown in the middle. A complete arcade, which normally has 16 natural teeth, can be replaced with six or eight implants.

Most implants are placed by using a two-step process. The surgical technique used is to place the implant at the level of the alveolar crest and cover it with the gum; the implant is uncovered 3 or 6 months later if there is enough bone. Nevertheless, in the most commonly used technique, the implant is left uncovered and the space is filled with a provisional crown, which may or may not have immediate load (contact with the antagonist teeth).

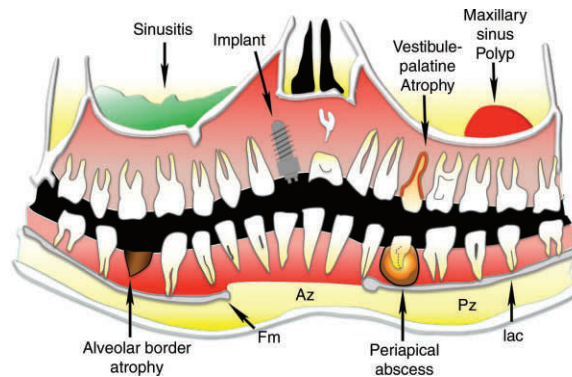
When dental implants are placed simultaneously with a cancellous bone graft and membrane, the waiting time to uncover them to allow good osseointegration is up to 8 months. If elevation of the maxillary sinus floor is required, this process has to be performed 6–8 months before implant placement. In the second stage, the fixtures of the implants are uncovered and checked for adequate osseointegration and the abutments are placed, thus allowing the prosthetic crown to be placed above the level of the gingiva (Fig 15).

Dental implants might fail because of infection, use of substandard fixtures, premature load put on the implant, and insufficient bone quality or nerve impingement (Figs 8, 10). In most cases, shortcutting the diagnostic phase by using only standard two-dimensional x-ray methods is an unnecessary risk taken by the surgeon, since with dental CT the three-dimensional questions about the exact positions of vital structures as well as the state of the bone can be answered in just a 3-minute exploration.

The anatomy and pathologic findings observed during preoperative evaluation for planning of dental implant placement are shown in Figure 16.

### Conclusions

The introduction of osseointegrated implants for the rehabilitation of edentulism allows the patient to be treated in a practical manner, giving the patient a functional and aesthetic alternative. Nowadays, most maxillary surgeons use dental CT for preoperative evaluation to avoid complications. This method is superior to conventional x-ray techniques, since superimposition and distortion are eliminated. This noninvasive and fast method provides accurate information about the positions of important structures to allow one to determine the implant required. Dental CT enables analysis of the state, quality, and quantity of bone on two-dimensional and three-dimensional reformatted images, and its high spatial resolution allows exact measurements of the length and width of the alveolar ridge.



**Figure 16.** Anatomy and pathologic findings observed during preoperative evaluation for planning of dental implant placement. *Az* = anterior zone, *Fm* = mental foramen, *Iac* = inferior alveolar canal, *Pz* = posterior zone.

### References

1. Adams C, Slack-Smith LM, Larson A, O'Grady MJ. Edentulism and associated factors in people 60 years and over from urban, rural and remote Western Australia. *Aust Dent J* 2003;48(1):10–14.
2. Steele JG, Sanders AE, Slade GD, et al. How do age and tooth loss affect oral health impacts and quality of life? A study comparing two national samples. *Community Dent Oral Epidemiol* 2004;32(2):107–114.
3. Marcenes W, Steele JG, Sheiham A, Walls AW. The relationship between dental status, food selection, nutrient intake, nutritional status, and body mass index in older people. *Cad Saude Publica* 2003;19(3):809–816.
4. Lee JS, Weyant RJ, Corby P, et al. Edentulism and nutritional status in a biracial sample of well-functioning, community-dwelling elderly: the health, aging, and body composition study. *Am J Clin Nutr* 2004;79(2):295–302.
5. U.S. Department of Health and Human Services, National Institute of Dental and Craniofacial Research, National Institutes of Health. Oral health in America: a report of the Surgeon General. Rockville, Md: U.S. Department of Health and Human Services, 2000.
6. Millar WJ, Locker D. Edentulism and denture use. *Health Rep* 2005;17(1):55–58.
7. Medina-Solis CE, Pérez-Núñez R, Maupomé G, Casanova-Rosado JF. Edentulism among Mexican adults aged 35 years and older and associated factors. *Am J Public Health* 2006;96(9):1578–1581.
8. Bianchi AE, Sanfilippo F. Osteoporosis: efecto sobre la reabsorción ósea del maxilar y posibilidades



- terapéuticas mediante prótesis sobre implantes—revisión bibliográfica y consideraciones clínicas. *Rev Int Odontol Restaur Periodon* 2003;7(5):483–494.
9. Lam EW, Ruprecht A, Yang J. Comparison of two-dimensional orthoradially reformatted computed tomography and panoramic radiography for dental implant treatment planning. *J Prosthet Dent* 1995;74(1):42–46.
  10. Matteson SR, Deahl ST, Alder ME, Nummikoski PV. Advanced imaging methods. *Crit Rev Oral Biol Med* 1996;7(4):346–395.
  11. Rothman SL, Chafetz N, Rhodes ML, Schwarz MS. CT in the preoperative assessment of the mandible and maxilla for endosseous implant surgery: work in progress. *Radiology* 1988;168(1):171–175. [Published correction appears in *Radiology* 1988;169(2):581.]
  12. Gahleitner A, Hofschneider U, Tepper G, et al. Lingual vascular canals of the mandible: evaluation with dental CT. *Radiology* 2001;220(1):186–189.
  13. Schwarz MS, Rothman SL, Rhodes ML, Chafetz N. Computed tomography. I. Preoperative assessment of the mandible for endosseous implant surgery. *Int J Oral Maxillofac Implants* 1987;2(3):137–141.
  14. Schwarz MS, Rothman SL, Rhodes ML, Chafetz N. Computed tomography. II. Preoperative assessment of the maxilla for endosseous implant surgery. *Int J Oral Maxillofac Implants* 1987;2(3):143–148.
  15. Scarfe WC, Farman AG, Sukovic P. Clinical applications of cone-beam computed tomography in dental practice. *J Can Dent Assoc* 2006;72(1):75–80.
  16. Miles DA. Clinical experience with cone-beam volumetric imaging: report of findings in 381 cases. *US Dent* 2006;1(1):39–41.
  17. Ludlow JB, Davies-Ludlow LE, Brooks SL, Howerton WB. Dosimetry of 3 CBCT devices for oral and maxillofacial radiology: CB Mercuray, NewTom 3G and i-CAT. *Dentomaxillofac Radiol* 2006;35(4):219–226.
  18. Almog DM, LaMar J, LaMar FR, LaMar F. Cone beam computerized tomography-based dental imaging for implant planning and surgical guidance. I. Single implant in the mandibular molar region. *J Oral Implantol* 2006;32(2):77–81.
  19. Kohavi D, Bar-Ziv J, Marmary Y. Effect of axial plane deviation on cross-sectional height in reformatted computed tomography of the mandible. *Dentomaxillofac Radiol* 1997;26(3):189–191.
  20. Abrahams JJ, Kalyanpur A. Dental implants and dental CT software programs. *Semin Ultrasound CT MR* 1995;16(6):468–486.
  21. Position statement on radiation risk. Health Physics Society Web site. [http://www.hps.org/documents/risk\\_ps010-1.pdf](http://www.hps.org/documents/risk_ps010-1.pdf). Published 2004.
  22. National Research Council. Report of the Committee on the Biological Effects of Ionizing Radiations: health effects of exposure to low levels of ionizing radiation. BEIR V. Washington, DC: National Academy Press, 1990; 175.
  23. Verdun FR, Bochud F, Gundinchet F, Aroua A, Schnyder P, Meuli R. Radiation risk: what you should know to tell your patient. *RadioGraphics* 2008;28(7):1807–1816.
  24. Suomalainen A, Kiljunen T, Käser Y, Peltola J, Korttesniemi M. Dosimetry and image quality of four dental cone beam computed tomography scanners compared with multislice computed tomography scanners. *Dentomaxillofac Radiol* 2009;38(6):367–378.
  25. Suomalainen A, Vehmas T, Korttesniemi M, Robinson S, Peltola J. Accuracy of linear measurements using dental cone beam and conventional multislice computed tomography. *Dentomaxillofac Radiol* 2008;37(1):10–17.
  26. La Fuente Martínez J, Oleaga Zufiria L. Monografía SERAM: radiología ortopédica y radiología dental—una guía práctica (Tardáguila/Del Cura). Mexico City, Mexico: Editorial Médica Panamericana, 2007; 99–110.
  27. Abrahams JJ. The role of diagnostic imaging in dental implantology. *Radiol Clin North Am* 1993;31(1):163–180.
  28. Abrahams JJ. Dental CT imaging: a look at the jaw. *Radiology* 2001;219(2):334–345.
  29. Cawood JI, Howell RA. A classification of the edentulous jaws. *Int J Oral Maxillofac Surg* 1998;17(4):232–236.
  30. Lekholm Y, Zarb GA. Patient selection and preparation. In: Branemark P, Zarb GA, Albrektsson T, eds. *Tissue integrated prostheses: osteointegration in clinical dentistry*. Chicago, Ill: Quintessence, 1985; 199–209.
  31. Norton MR, Gamble C. Bone classification: an objective scale of bone density using the computerized tomography scan. *Clin Oral Implants Res* 2001;12(1):79–84.
  32. DelBalso AM. An approach to the diagnostic imaging of jaw lesions, dental implants, and the temporomandibular joint. *Radiol Clin North Am* 1998;36(5):855–890.

## Dental Multisection CT for the Placement of Oral Implants: Technique and Applications

*Jaime A. Saavedra-Abril, MD • Claudia Balhen-Martin, MD • Kena Zaragoza-Velasco, MD • Eric T. Kimura-Hayama, MD • Santiago Saavedra, MD • Miguel E. Stoopen, MD*

RadioGraphics 2010; 30:1975–1991 • Published online 10.1148/rg.307105026 • Content Codes:    

### Page 1976

Several intraoral and extraoral radiographic methods such as periapical, occlusal, panoramic, and motion tomography are commonly available for evaluation of the implant recipient site, but the information is based on bidimensional geometric projections (9).

### Page 1977

There are different numbering methods; the most common and practical starts from the right side of the maxilla (last superior molar) and goes to the left upper quadrant (numbers 1–16), then continues from tooth number 17 in the posterior left side of the mandible to tooth number 32 in the posterior right side, forming a bow numeration or a circle out of the maxillary and mandibular arches.

### Page 1980

The advantages of dental CT include elimination of superimpositions. It also allows distinction of opacity differences between two tissues (ie, contrast resolution), and further image projections or planar reformations can be performed (9).

### Page 1982 (Figures on pages 1979 and 1980)

The perpendicular lines marked along the superimposed curve indicate the positions of the sagittal oblique reformatted images on the axial section and the levels of the reformatted images, thus providing data on the height and depth of every image. The numbering of these lines starts in the right posterior zone and ends in the left posterior zone. Such parameters may vary slightly from program to program (26) (Figs 5, 6).

### Page 1982

The sagittal oblique images are the most representative and important images in dental CT, since the shape, angulation, and measurements of height and thickness of the alveolar bone are determined on the basis of these images (20).