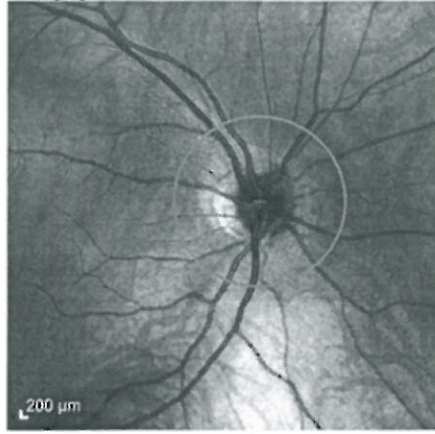
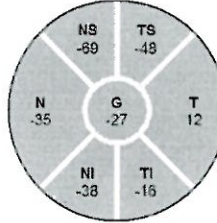
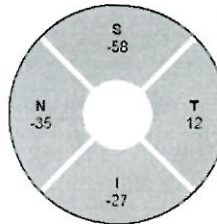


OD

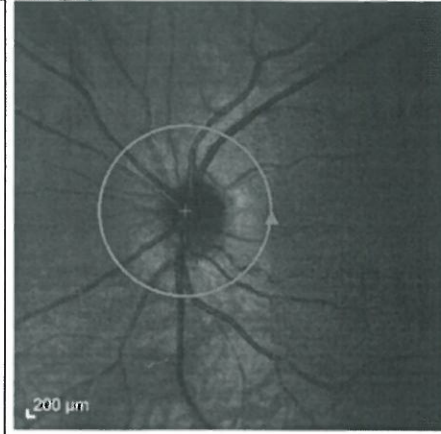
IR 30° [HS]



Asymmetry
OD - OS

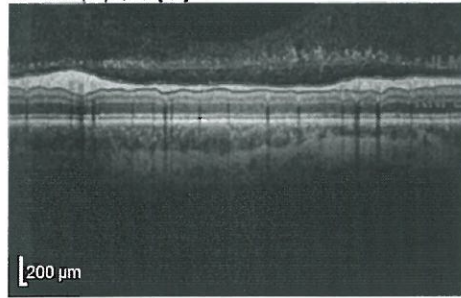


IR 30° [HS]

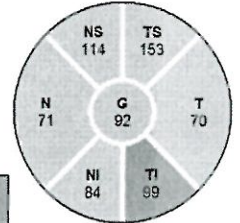
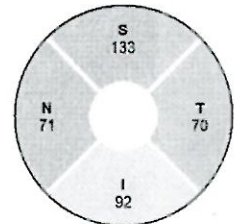
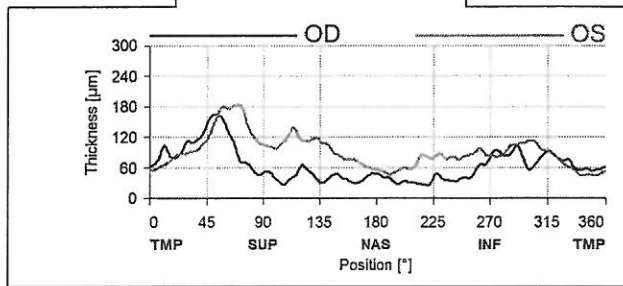
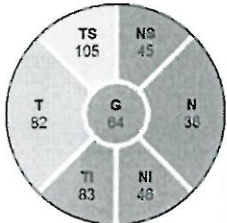
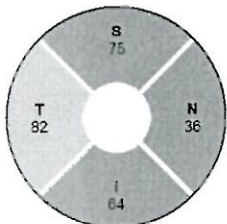
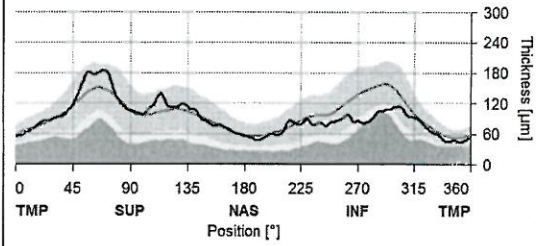
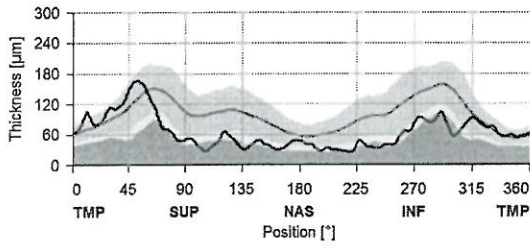
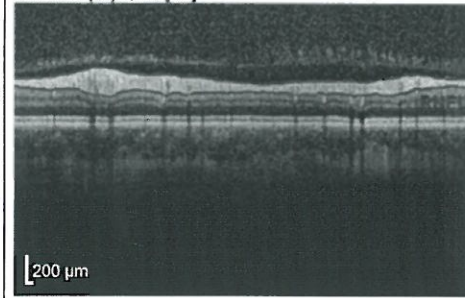


OS

OCT ART (16) Q: 29 [HS]



OCT ART (25) Q: 16 [HS]



Classification OD

Outside Normal Limits

Classification OS

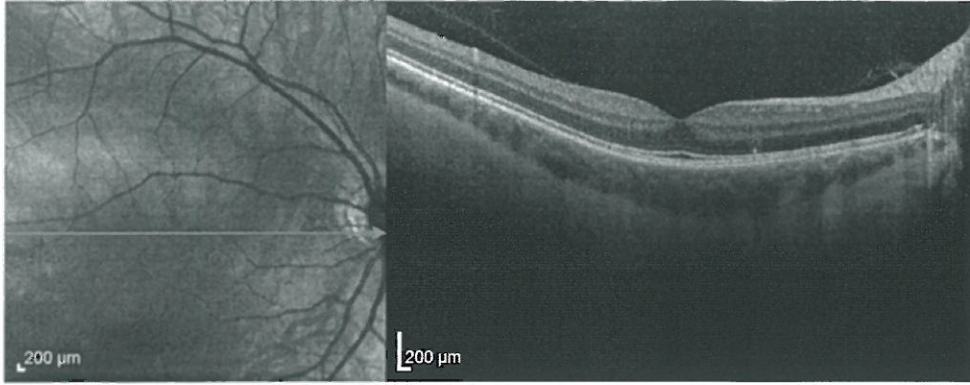
Outside Normal Limits

Notes:

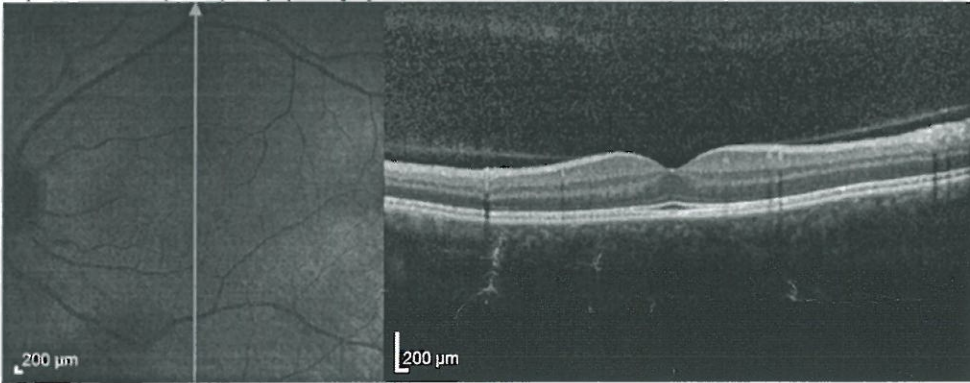
of previous report
Signature: *[Handwritten Signature]*

Date: 12.08.2014

OD, IR 30° + OCT 30° (8.8 mm) ART (19) Q: 27 [HS]



OS, IR 30° + OCT 30° (8.8 mm) ART (25) Q: 22 [HS]



Од- томерет сетови
в центр в шее -
на нерв
контур шее
не нерв

Notes:

Date: 12.08.2014

Signature: