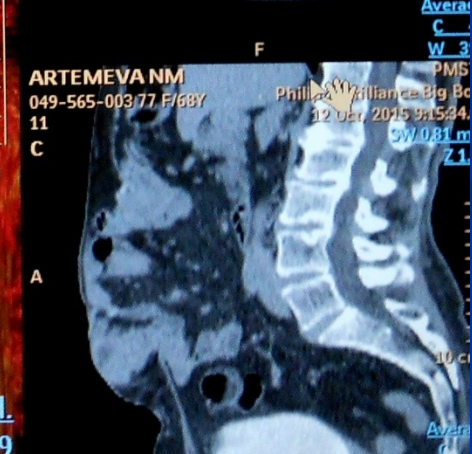
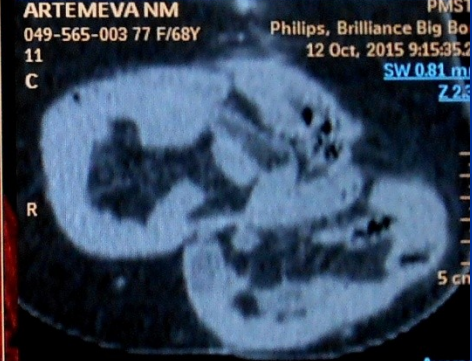
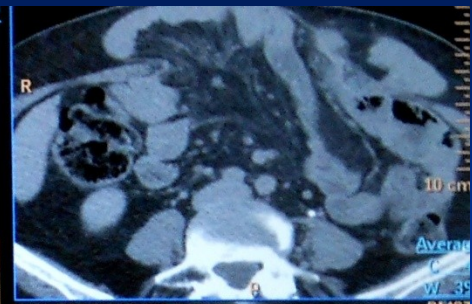
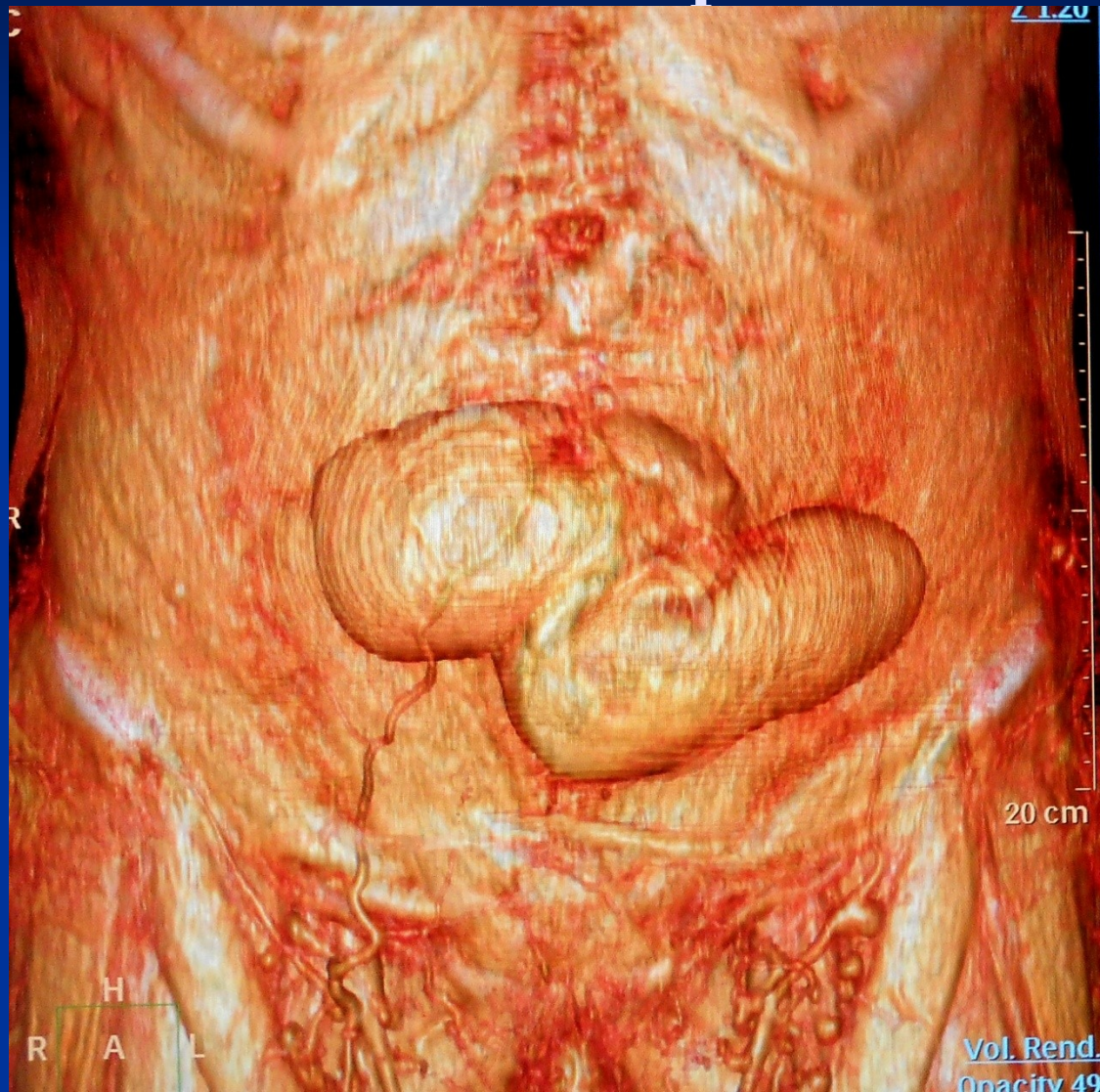


**Вентральная грыжа передней
брюшной стенки.
МСКТ. Наблюдение из практики.**

Бодров Ю.Д.

Кандидат медицинских наук

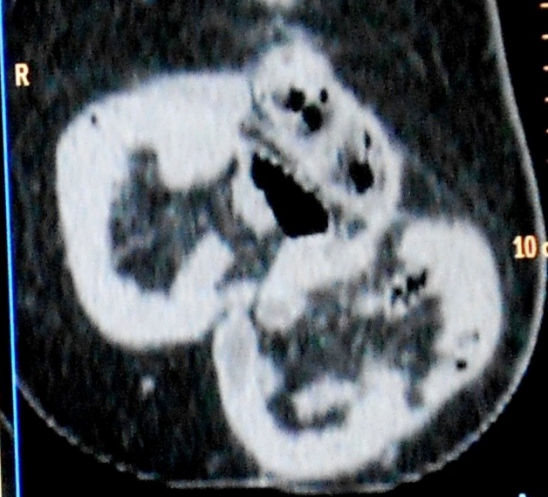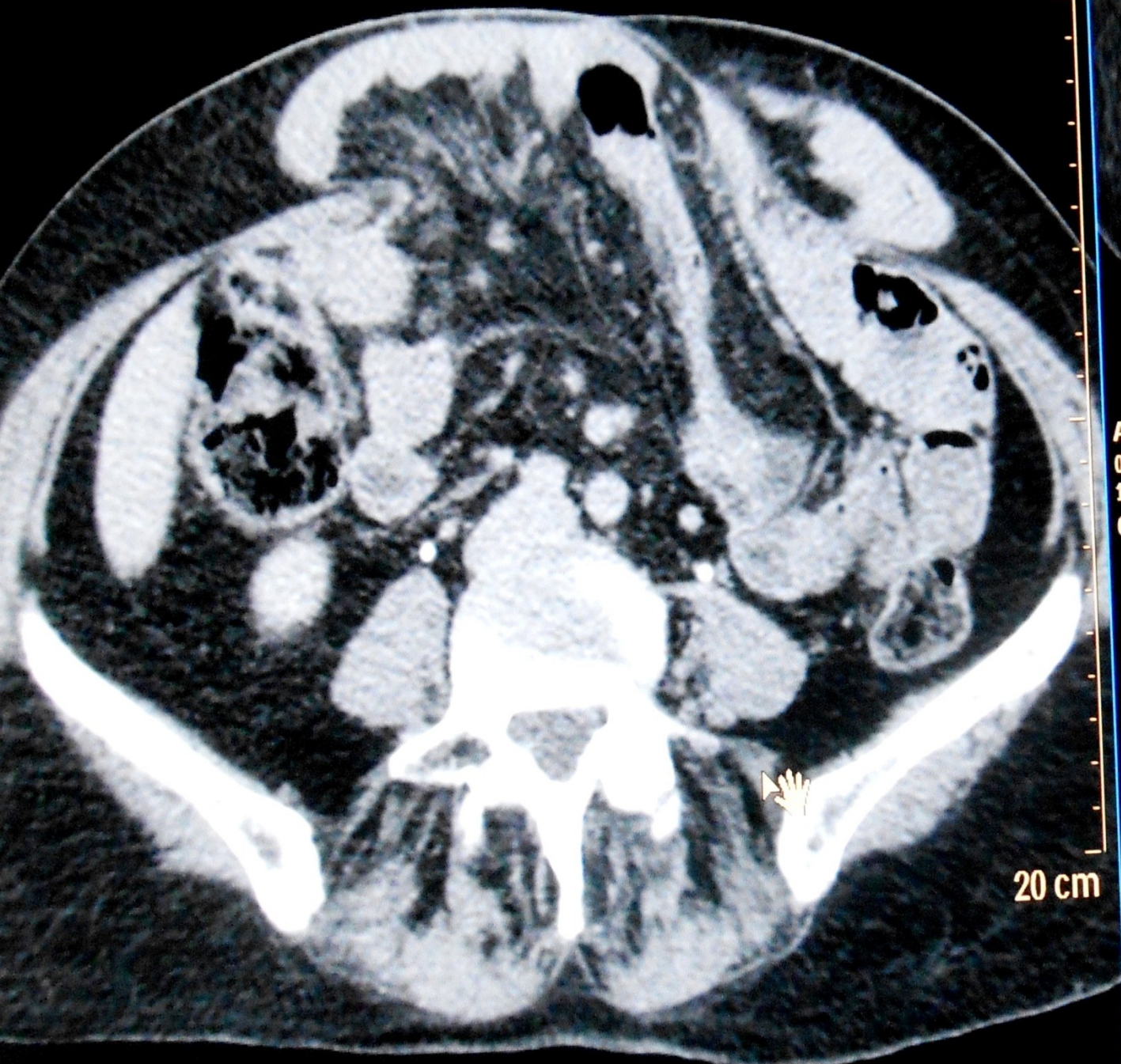Больная А. 77 лет. Вентральная грыжа передней брюшной стенки. Камни желчного пузыря. Парапелльвикальные кисты правой почки



ARTEMEVA NM
049-565-003 77 F/68Y
11
C
Philips, Brilliance Big Bo
12 Oct, 2015 9:15:52
SW 0.81 m
Z 2.6

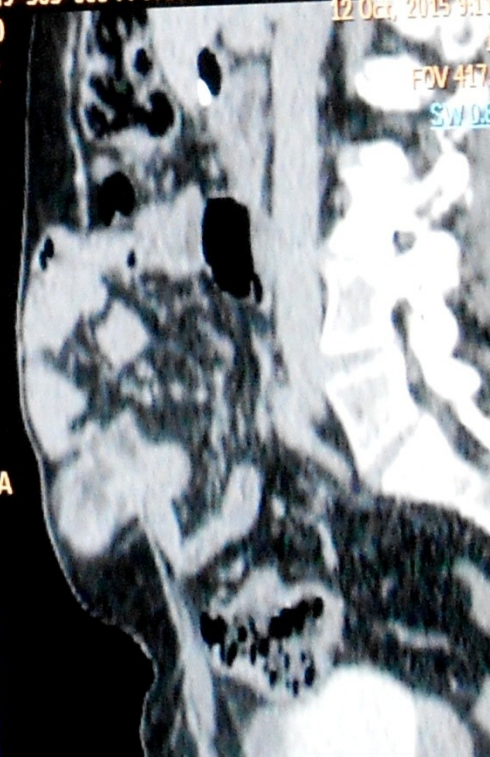
ARTEMEVA NM
049-565-003 77 F/68Y
11
C
Philips, Brilliance Big Bo
12 Oct, 2015 9:15:44
SW 0.81 m
Z 1.1

Vol. Rend.
Opacity 49

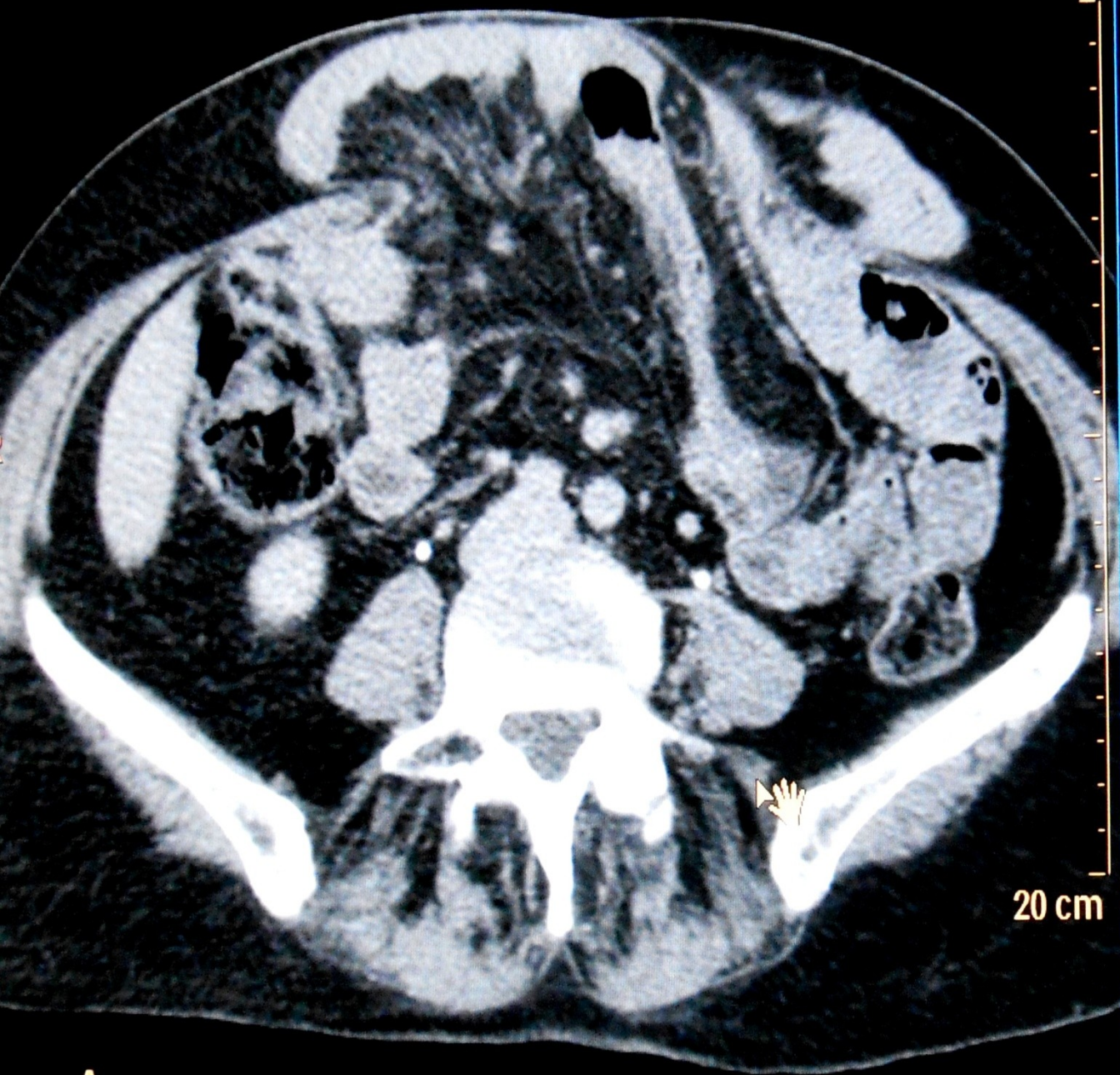


ARTEMEVA NM
049-565-003 77 F/68Y
10
C

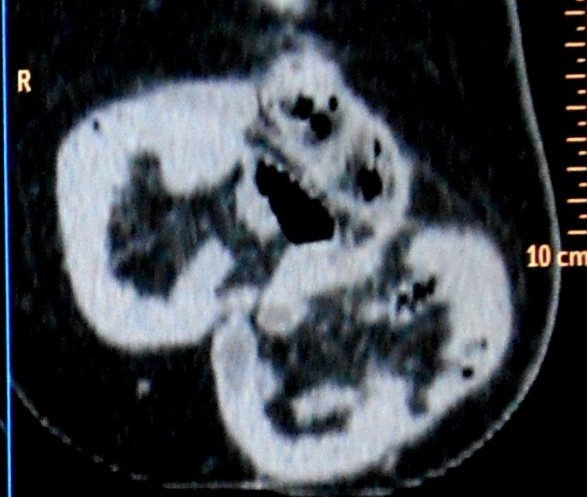Philips, Brilliance Big
12 Oct, 2015 9:11



A



A

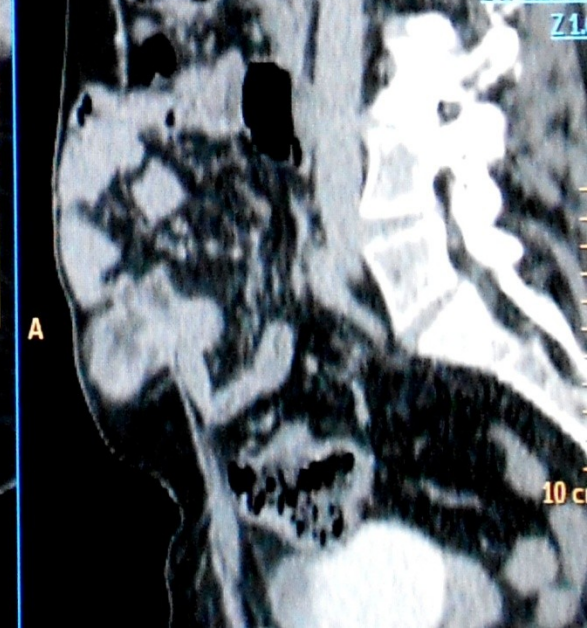

Average
C 6
W 40
PMS

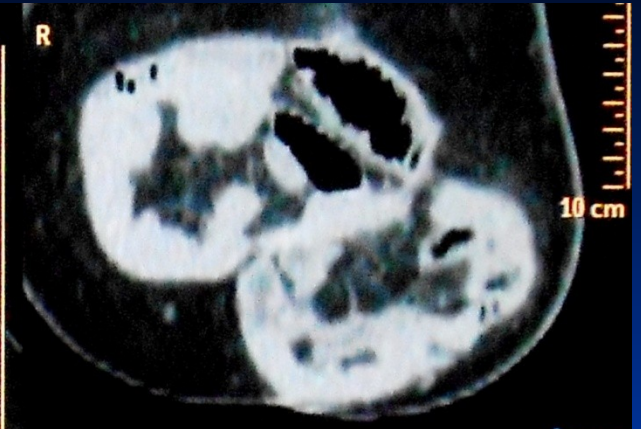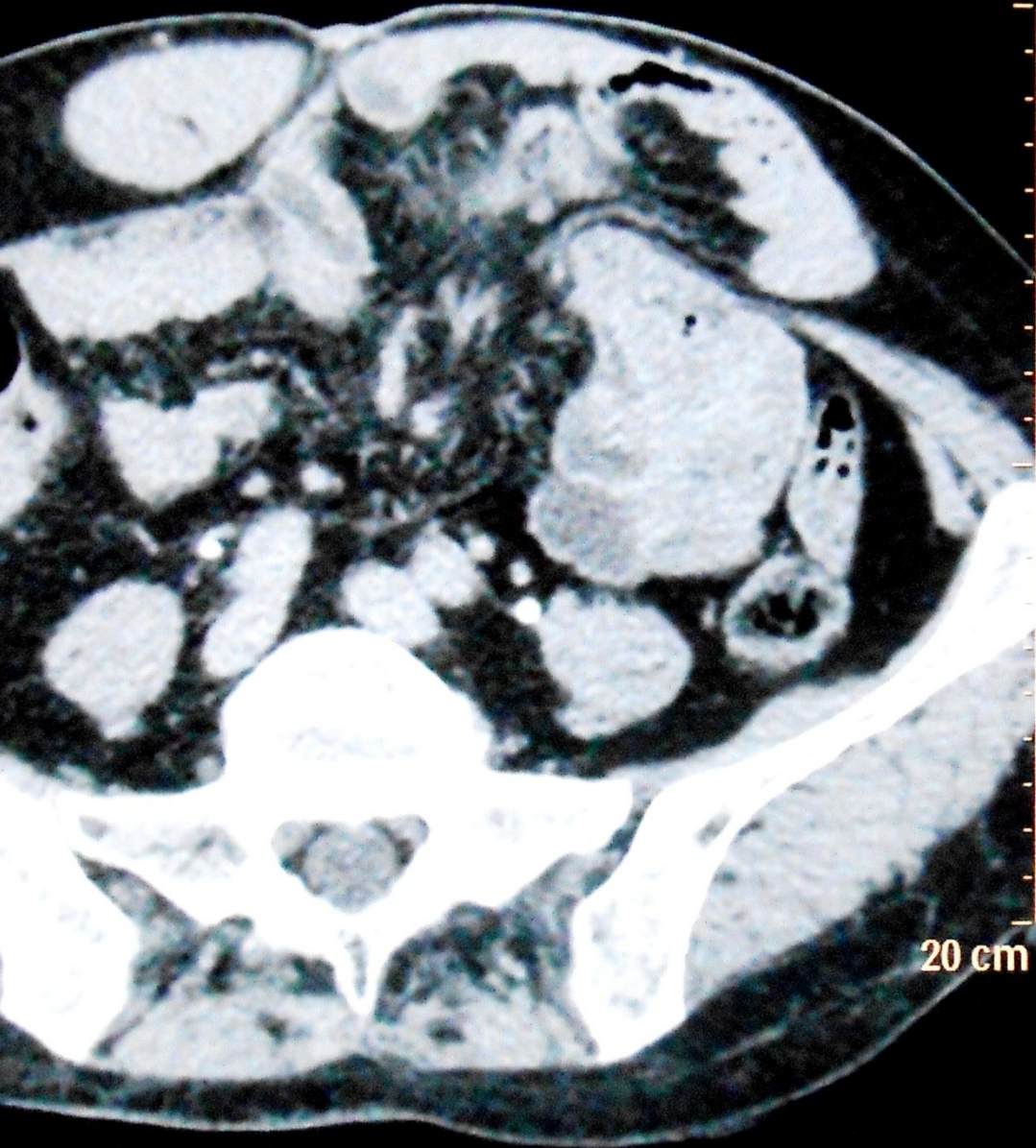
ARTEMEVA NM Philips, Brilliance Big Bo

049-565-003 77 F/68Y 12 Oct, 2015 9:11:30

10
C
120 kV
FOV 417.0 mm
SW 0.81 mm
Z1

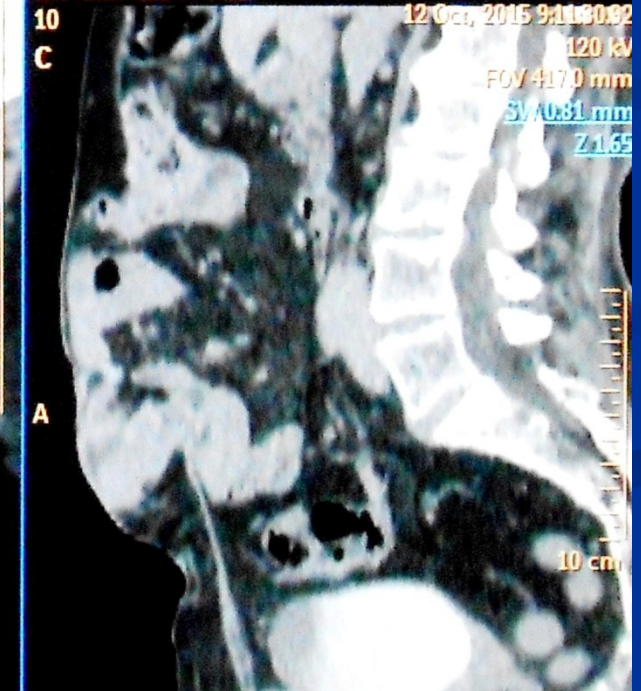


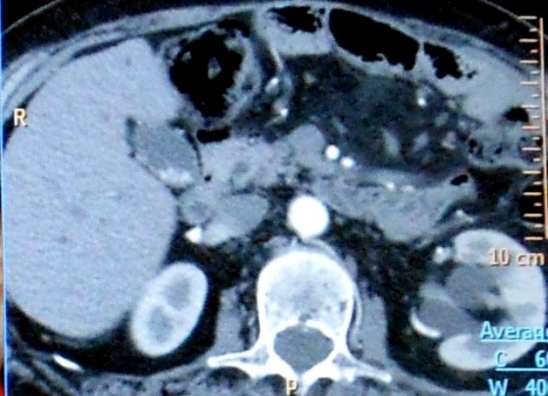
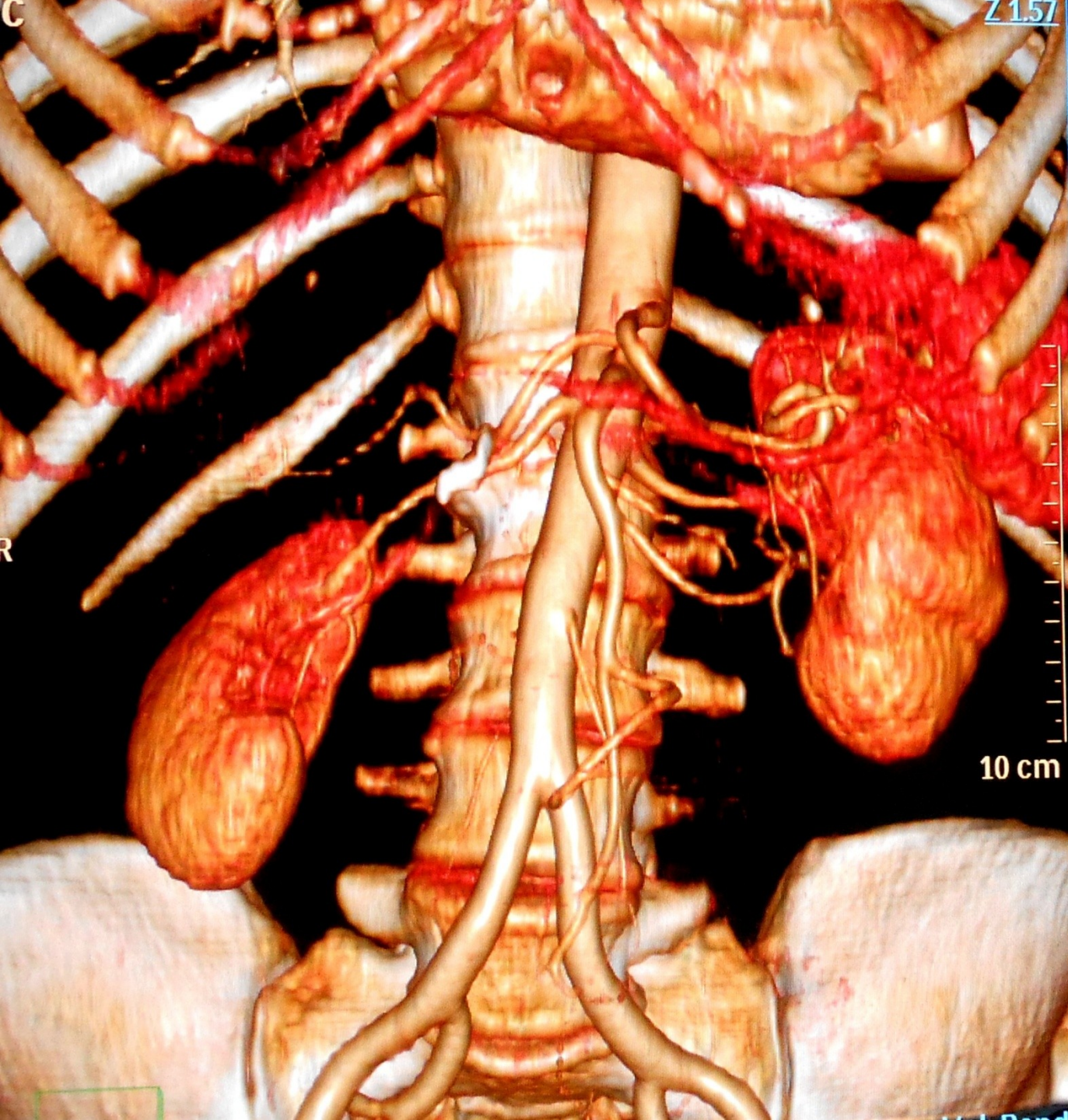
A



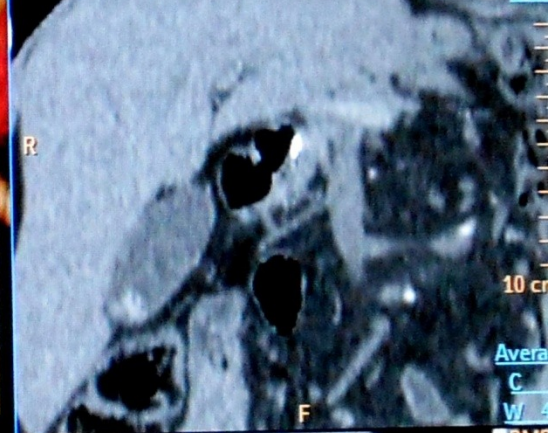
Average
C 60
W 400
PMSTL

ARTEMEVA NM
049-565-003 77 F/68Y
10
C
Philips, Brilliance Big Bore
12 Oct, 2015 9:11:30.92
120 kV
FOV 417.0 mm
SV 0.81 mm
Z 165





ARTEMEVA NM
049-565-003 77 F/68Y
7
C
Philips, Brilliance Big B
12 Oct, 2015 9:05:23
SW 0.80 mm
Z1.7



ARTEMEVA NM
049-565-003 77 F/68Y
7
C
Philips, Brilliance Big B
12 Oct, 2015 9:05:25
SW 0.80 mm
Z1.7

